

ESSENTIAL OCULAR ONCOLOGY

A Guide for Practitioners

Bertil Damato, Gordon Hay, Amit Arora,
Guy Negretti & Mandeep Sagoo

(CLICK ON ITEM IN CONTENTS TO JUMP TO RELEVANT PAGE AND CLICK RED SIDEBAR ON PAGE TO RETURN HERE)

CONTENTS

CONTENTS	2
PREFACE	7
DETECTION OF OCULAR TUMOURS	8
INVESTIGATION	9
HISTORY	9
VISUAL ACUITY	9
CONJUNCTIVAL EXAMINATION	9
EXTRAOCULAR TUMOUR	10
PREDISPOSING CONDITIONS FOR CONJUNCTIVAL MALIGNANCY	10
ANTERIOR SEGMENT EXAMINATION	11
ANTERIOR SEGMENT TUMOUR	11
SECONDARY EFFECTS	11
PREDISPOSING CONDITIONS FOR INTRAOCULAR TUMOURS	11
POSTERIOR SEGMENT EXAMINATION	12
POSTERIOR SEGMENT TUMOUR	12
SECONDARY EFFECTS	12
THREE-MIRROR EXAMINATION	12
TRANSILLUMINATION	12
COLOUR PHOTOGRAPHY	13
FUNDUS AUTOFLUORESCENCE (FAF)	14
FLUORESCEIN ANGIOGRAPHY	15
INDOCYANINE-GREEN ANGIOGRAPHY (ICG)	15
OPTICAL COHERENCE TOMOGRAPHY (OCT)	15
ULTRASONOGRAPHY (US)	16
METHODS:	17
TUMOUR BIOPSY	18
EXCISIONAL BIOPSY	19
INCISIONAL BIOPSY	19
	2

ASPIRATION BIOPSY	19
CONJUNCTIVAL IMPRINT CYTOLOGY	20
LIQUID BIOPSY	20
COMPUTERISED TOMOGRAPHY (CT)	20
MAGNETIC RESONANCE IMAGING (MRI)	20
OCULAR TUMOURS	21
UVEAL MELANOMA	21
CLINICAL FEATURES	21
CLINICAL INVESTIGATIONS	22
LABORATORY INVESTIGATIONS	22
TREATMENT	24
OCULAR RESULTS OF CONSERVATIVE THERAPY	29
METASTATIC DISEASE FROM UVEAL MELANOMA	29
COUNSELLING	30
FOLLOW UP	31
CHOROIDAL NAEVUS	32
MOLES SCORING SYSTEM	32
IRIS NAEVUS	35
MELANOCYTOMA	35
IRIS FRECKLE	36
LISCH NODULES	36
CONGENITAL OCULAR MELANOCYTOSIS	36
CHOROIDAL HAEMANGIOMA	37
DOME-SHAPED MACULA	38
CHOROIDAL OSTEOMA	38
SCLERO-CHOROIDAL CALCIFICATION	39
IDIOPATHIC OCULAR SCLEROMA	39
NEUROFIBROMA, NEURILEMMOMA AND LEIOMYOMA	39
ASTROCYTIC HAMARTOMA	39
RETINAL CAVERNOUS ANGIOMA	40
RACEMOSE ANGIOMA	40
RETINAL HAEMANGIOBLASTOMA	40

VASOPROLIFERATIVE TUMOUR	41
RETINOBLASTOMA	41
MEDULLOEPITHELIOMA	42
CONGENITAL HYPERTROPHY OF THE RPE (CHRPE)	42
TORPEDO MACULOPATHY	43
IRIS CYSTS	43
IRIS ARTERIOVENOUS MALFORMATION	44
ADENOMA AND ADENOCARCINOMA	44
COMBINED HAMARTOMA OF THE RPE AND RETINA	45
INTRAOCULAR METASTASIS	45
VITREORETINAL LYMPHOMA	46
PRIMARY UVEAL LYMPHOMA	47
OTHER HEMATOLOGICAL MALIGNANCIES	48
PARANEOPLASTIC SYNDROMES	48
CONJUNCTIVAL MELANOMA	48
PRIMARY ACQUIRED CONJUNCTIVAL MELANOSIS (PAM)	50
CONJUNCTIVAL NAEVUS	51
CONJUNCTIVAL PAPILLOMA	51
OCULAR SURFACE SQUAMOUS NEOPLASIA	51
INVASIVE CONJUNCTIVAL CARCINOMA	52
SEBACEOUS GLAND CARCINOMA	53
CONJUNCTIVAL LYMPHOMA	53
CHORISTOMA	54
PATIENT REFERRAL TO GENERAL OPHTHALMOLOGIST BY OPTOMETRIST	55
Examination	55
INDICATIONS FOR REFERRAL	55
METHOD OF REFERRAL	55

CONDITIONS NOT NEEDING REFERRAL	55
PATIENT REFERRAL TO OCULAR ONCOLOGIST	57
INDICATIONS FOR REFERRAL	57
METHOD OF REFERRAL	57
CONDITIONS NOT NEEDING REFERRAL	57
MONITORING	59
INDICATIONS	59
COUNSELLING	62
FOLLOW-UP BY LOCAL OPHTHALMOLOGIST	63
IMMEDIATE POST-OPERATIVE PERIOD	63
LONG-TERM TUMOUR MONITORING	63
DIAGNOSTIC AND THERAPEUTIC PROCEDURES AT LOCAL HOSPITAL	66
CATARACT SURGERY	66
GLAUCOMA SURGERY	66
STRABISMUS SURGERY	66
TREATMENT FOR MACULAR oedema	66
TREATMENT FOR EXUDATIVE RETINAL DETACHMENT	67
PREVENTION OF TOXIC-TUMOUR SYNDROME	67
ENUCLEATION	67
REMOVAL OF EXTRUDING TANTALUM MARKER	67
BIOPSY OF CONJUNCTIVAL PRIMARY ACQUIRED MELANOSIS	67
EXCISION BIOPSY OF NODULAR CONJUNCTIVAL TUMOURS	68
VITREORETINAL LYMPHOMA BIOPSY	68
CATARACT SURGERY	68
GLAUCOMA SURGERY	68
STRABISMUS SURGERY	68
MANAGEMENT OF DRY EYE	68
MANAGEMENT OF MEIBOMIAN GLAND DYSFUNCTION	69
MANAGEMENT OF LIMBAL STEM-CELL DEFICIENCY	69
TENTATIVE GUIDELINES FOR REGIONAL OCULAR ONCOLOGY SERVICES	70
INTRODUCTION	70
OCULAR ONCOLOGY SERVICE	70
CORE TEAM	70
ASSOCIATES	71
OCULAR ONCOLOGY Clinics	71
FACE-TO-FACE CLINIC	71

'VIRTUAL' CLINICS	71
ADMINISTRATIVE CLINIC	72
PROTOCOLS	72
OPTOMETRISTS	72
NON-ONCOLOGY OPHTHALMOLOGISTS	72
OCULAR ONCOLOGY SPECIALISTS	72
OTHERS	72
FURTHER READING	73

PREFACE

Optometrists and ophthalmologists play a major role in the management of ocular tumours. This can be challenging because of the rarity of these tumours and the severe consequences that can occur if a condition is missed, misdiagnosed or mis-managed. As a result, there is a tendency to 'err on the side of safety'.

Although perfectly understandable, this approach may result in non-essential hospital visits, unnecessary investigations, and a reluctance to transfer long-term surveillance to a practitioner close to the patient's home. Such excessive care diverts limited NHS resources from patients in greater need, lengthening waiting lists so that opportunities for conserving vision, and perhaps life itself, may be missed. Apart from overburdening healthcare services, unnecessary care also incurs costs for the patients themselves, also needlessly causing them inconvenience and anxiety.

We hope that this guide will make it easier and safer for the care of these patients to be transferred from supraregional ocular oncology centres to their local eye hospital and from there to their community optometrist. By reducing waste and inefficiency, we hope to improve the standard of care delivered to patients with ocular tumours and, indeed, to all patients.

This guide focuses on the most common conditions and treatments. It is not meant to be encyclopaedic. This is to reduce the file-size of this e-book so that it can be conveniently shared by e-mail.

Items of interest can be found by clicking on the relevant topic in the contents page or by performing a word search. You can quickly return to the contents page by clicking on the red bar at the side of each page.

Further information can be found by hovering on relevant text, which is highlighted in blue, and clicking on the text to reach the PubMed citation.

We hope to update this guide regularly and would be most grateful for any comments, corrections or suggestions, which you can e-mail to

Bertil.Damato@NHS.net

3rd January 2025

Prof. Bertil Damato
Consultant ocular oncologist, Moorfields Eye Hospital, Oxford Eye Hospital & St. Erik Eye Hospital, Stockholm. Emeritus Professor of Ophthalmology & Radiation Oncology, University of California, San Francisco.



Dr. Amit Arora
Senior Ocular Oncologist & Staff Governor, Moorfields Eye Hospital, London, UK



Dr. Gordon Hay
Senior Ocular Oncologist & Service Director of A&E, Moorfields Eye Hospital; Deputy Director of Education Institute of Ophthalmology, London, UK



Mr. Guy Negretti
Ocular Oncologist, Moorfields Eye Hospital; Consultant Ophthalmic Surgeon, Surrey and Sussex Healthcare NHS Trust

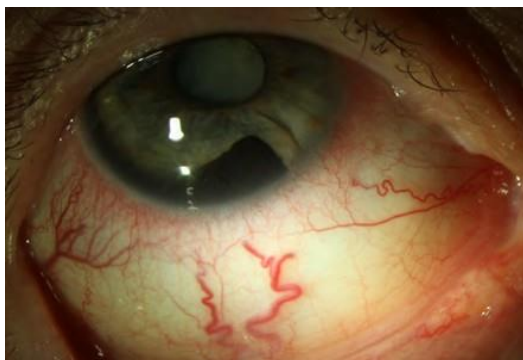

Prof. Mandeep Sagoo
Professor of Ophthalmology and Ocular Oncology, UCL Institute of Ophthalmology; Consultant Ophthalmic Surgeon, Moorfields Eye Hospital & Barts Health NHS Trust, London, UK



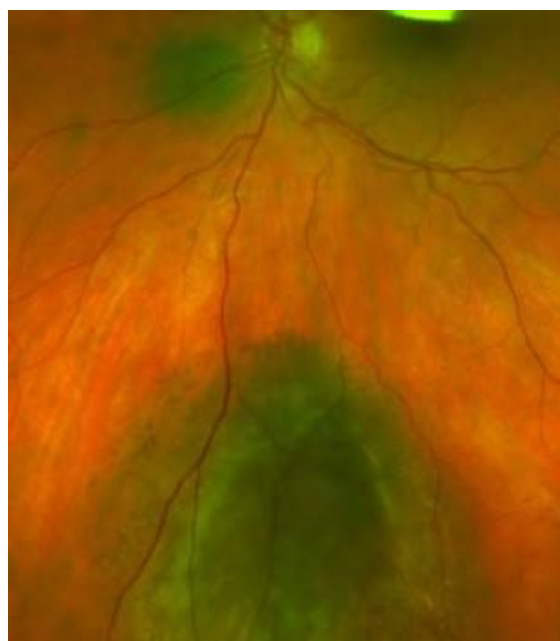DETECTION OF OCULAR TUMOURS

Many asymptomatic tumours are detected by routine screening, for example, performing bilateral ophthalmoscopy when the patient has presented for new spectacles. However, it is not uncommon for patients to present with a symptomatic choroidal tumour soon after having an eye examination, suggesting perhaps that the ophthalmoscopy was limited to optic disc and macula. A significant proportion of patients with uveal melanoma report that their tumour was not detected when they first presented on account of symptoms. In comparison with symptomatic patients whose tumour is immediately detected, such individuals experience longer delays in obtaining treatment and are also more likely to lose vision and the eye.



Sentinel vessels overlying a ciliary body melanoma that has invaded the anterior chamber

There is no consensus as to whether both pupils should be dilated in all patients or only if there are any specific indications. It is beyond the scope of these guidelines to comment on what is acceptable in routine practice in the UK.



Peripheral choroidal melanoma, which would have been missed if the examiner had focused only on 'disc and macula' and the juxtapapillary choroidal naevus

INVESTIGATION

HISTORY

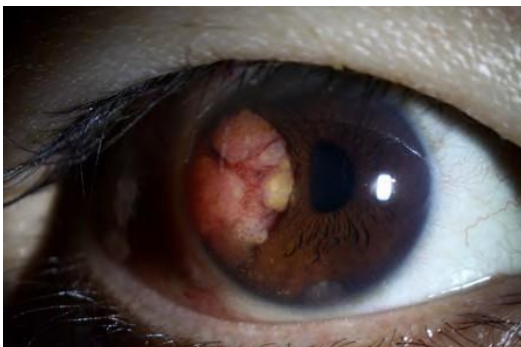It is necessary to obtain a full history including:

- Ocular symptoms, and their duration.
- Systemic enquiry
- Past ocular and systemic history.
- Family history of ocular and systemic disease.
- Topical and systemic medications.
- Present and past history regarding smoking, alcohol and other habits.
- Allergies.
- Social and occupational status, not least to understand the patient's visual needs.

The history can sometimes provide diagnostic clues, for example, if the patient has been a heavy smoker for many years or if a previous mastectomy has been performed. While such information might suggest the source of an intraocular metastasis, it should not be relied upon to distinguish between a metastasis and other types of tumour, such as melanoma and haemangioma. This is because dual pathology is not uncommon.

The history also provides an understanding of the patient's visual needs, which may help in the selection of the most appropriate form of treatment.

The duration of the visual loss can have prognostic significance; for example, in patients with choroidal haemangioma, visual loss is irreversible if longstanding.



Iris tumour in a 51-year-old woman with a history of breast cancer with systemic metastases. Ocular metastasis was confirmed.

VISUAL ACUITY

Ideally, visual acuity is measured using a LogMAR chart, which overcomes the limitations of the Snellen test.

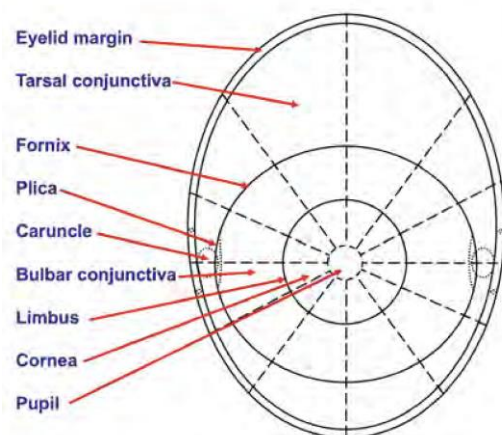
CONJUNCTIVAL EXAMINATION

When the patient has a conjunctival tumour, it is essential to examine the entire conjunctiva. The superior fornix can be inspected by gently pinching the eyelid skin and pulling the eyelid away from the globe, using a binocular indirect ophthalmoscope and 20 D lens.

Palpation of the pre- and post-auricular, cervical and submandibular areas is performed routinely, to detect any lymph node enlargement.

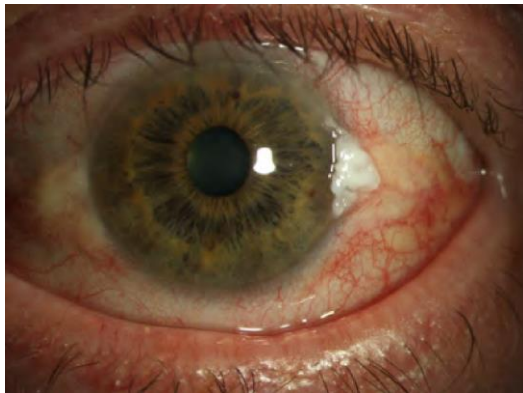
In addition to assessing the primary tumour, it is useful to document any secondary effects, identify any predisposing factors and recognise any concurrent disease.

Damato has devised a diagram that shows the entire conjunctival surface unobstructed by half-closed eyelids.



Template for drawing conjunctival tumours

EXTRAOCULAR TUMOUR



Conjunctival carcinoma at the temporal limbus of the left eye

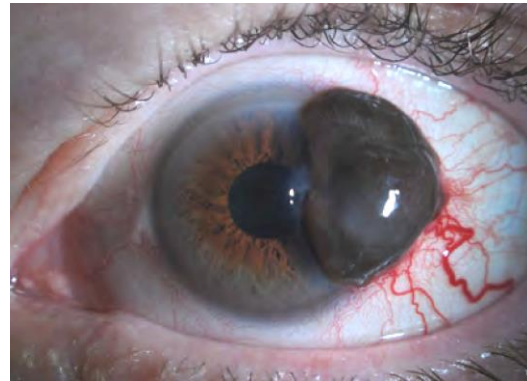A primary conjunctival or corneal tumour is described according to:

- Most likely site of origin (i.e., conjunctiva, cornea, intraocular structures, eyelid).
- Quadrant (i.e., superior, supero-nasal, nasal, etc.).
- Circumferential spread, which is measured in clock minutes in a clockwise direction (e.g., 5 to 30 or 55 to 5). This is easier than using degrees and more precise than clock hours. Circumferential spread can be described separately at limbus, bulbar conjunctiva, palpebral conjunctiva, etc.
- Posterior extent (e.g., cornea, limbus, bulbar conjunctiva).
- Anterior extent (e.g., fornix, palpebral conjunctiva, lid margin, skin).
- Consistency (i.e., solid, cystic, multicystic).
- Distortion of normal anatomy.
- Shape (i.e., flat, dome, unifocal-multinodular, multifocal).
- Margins (i.e., diffuse, discrete).
- Colour (i.e., pink, white, tan, etc.).
- Vascularity (present or absent).
- Seeding (i.e., across conjunctiva, into cornea, etc.).
- Deep invasion (i.e., conjunctival stroma, sclera, and intraocularly)
- Longitudinal and transverse basal dimensions, using the measure on the slit-lamp
- Extraocular spread (i.e., pre-auricular, sub-mandibular nodes, etc.)

SECONDARY EFFECTS OF EXTRAOCULAR TUMOUR

These include features such as:

- Feeder vessels.
- Infection.
- Haemorrhage.

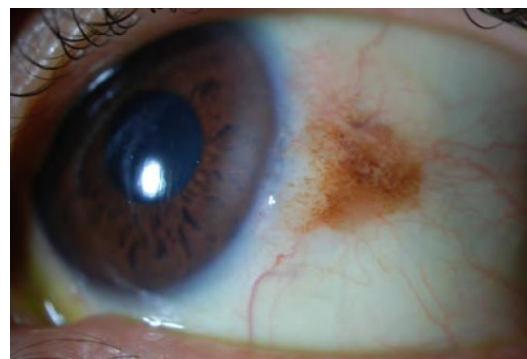


Feeder vessels supplying a conjunctival melanoma of the left eye

PREDISPOSING CONDITIONS FOR CONJUNCTIVAL MALIGNANCY

These include conditions such as:

- Primary acquired melanosis.
- Eyelid sebaceous gland carcinoma, which can recur in a pagetoid fashion in conjunctiva.
- Actinic keratosis.



Primary acquired melanosis of the left eye, which predisposes to invasive melanoma

CONCURRENT DISEASE

Concurrent disease at the time of presentation or caused by the ocular treatment includes:

- Keratoconjunctivitis sicca.
- Marginal keratitis.
- Ingrowing lashes.

Investigation should include:

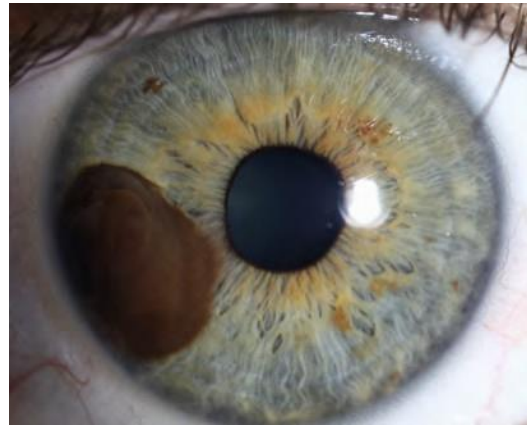- History: ocular surface disease index
- Tear film: meniscus, breakup time (6 ± 3 seconds), Shirmer test: 12 ± 5 mm
- Meibomian gland orifices: patent/occluded, squamous metaplasia
- Meibomian gland secretions: clear & fluid vs cloudy and viscous
- Lid margin: vascularity, irregularity, metaplasia
- Cornea: staining, ulceration, oedema, infiltrates
- Conjunctiva: staining, inflammation
- Episclera & sclera: hyperaemia, infiltrates

ANTERIOR SEGMENT EXAMINATION

ANTERIOR SEGMENT TUMOUR

The tumour is described according to:

- Most likely site of origin (i.e., iris, ciliary body, choroid).
- Quadrant (i.e., superior, supero-nasal, etc)
- Circumferential spread, ideally in clock minutes in a clockwise direction (e.g., 5 to 30 or 55 to 5).
- Posterior extent (e.g., choroid, pars plana, pars plicata, pupil margin, iris surface).
- Anterior extent (e.g., iris surface, angle, cornea).
- Longitudinal and transverse basal dimensions, using the measure on the slit-lamp. (See below for ultrasonography).
- Consistency (i.e., solid, cystic, multicystic).
- Shape (i.e., flat, dome, multinodular).
- Margins (i.e., diffuse, discrete).
- Colour (i.e., pink, white, tan, etc.).
- Vascularity (present or absent).
- Seeding (i.e., across iris or into angle).
- Angle involvement (i.e., in clock minutes).
With melanoma, it can be difficult to distinguish tumour from melanomacrophages clinically
- Extraocular spread (i.e., absent, nodular, diffuse).



Iris melanoma

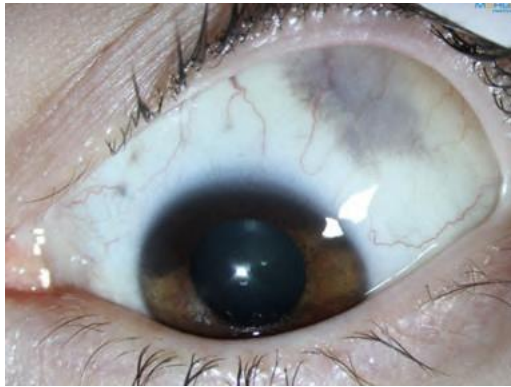
SECONDARY EFFECTS

These include:

- Glaucoma.
- Lens abnormality (e.g., cataract, deformity, subluxation).
- Dilated episcleral vessels, in the presence of ciliary body involvement.
- Iris cyst formation.
- Ectropion uvae.
- Pupillary peaking.
- Hyphaemia.
- Band keratopathy.

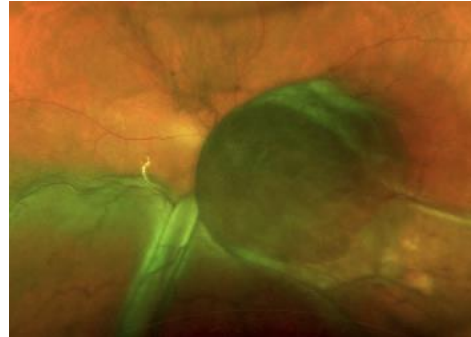
PREDISPOSING CONDITIONS FOR INTRAOCULAR TUMOURS

- Ocular or oculodermal melanocytosis (uveal melanoma).
- Sturge-Weber syndrome (diffuse choroidal haemangioma) and other vascular malformations.
- [BAP1 Tumour Predisposition Syndrome](#) (uveal melanoma)
- [MBD4-associated neoplasia syndrome](#) (uveal melanoma)
- *DICER1* Tumour Predisposition Syndrome (medulloepithelioma)
- [Congenital hypertrophy of the RPE](#) (adenoma/adenocarcinoma)



Congenital ocular melanocytosis with slate-grey subconjunctival pigmentation supero-temporally and with sectorial iris pigmentation supero-nasally in the left eye of a child.

- Haemorrhage (i.e., subretinal, vitreous, etc.)
- Cataract.
- Glaucoma.



Choroidal melanoma that has perforated Bruch's membrane, retinal pigment epithelium and retina, which is detached.

POSTERIOR SEGMENT EXAMINATION

POSTERIOR SEGMENT TUMOUR

To describe a posterior segment tumour, as many of the following features as possible should be noted:

- Tissue of origin (e.g., choroid, retina, RPE).
- Shape (e.g., dome, mushroom, etc.).
- Margins (i.e., discrete, diffuse).
- Tissue colour (e.g., grey, pink, white, etc.).
- Vascularity (e.g., vascular, avascular).
- Quadrant (e.g., superior, etc).
- Posterior extent, including distances to optic disc and fovea.
- Anterior extent (i.e., post-equatorial, pre-equatorial, pars plicata, angle, etc.).
- Circumferential involvement of optic disc and ciliary body (e.g., in clock minutes).
- Internal spread (e.g., sub-retinal space, retina, vitreous).
- Size (i.e., longitudinal, transverse and largest basal dimensions, and thickness).

SECONDARY EFFECTS

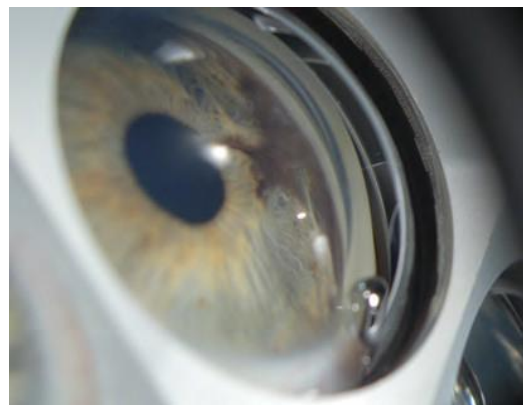The presence of any secondary effects should be recorded, which include:

- RPE changes overlying tumour (i.e., drusen, orange pigment, neovascular membrane).
- RPE changes adjacent to tumour (i.e., marginal atrophy, cobblestone degeneration, 'comet's tail' or 'peacock tail' atrophy). Exudative retinal detachment (i.e., over tumour surface, inferior retina, with an estimate of the percentage of retina detached).

THREE-MIRROR EXAMINATION

The indications are to:

- Identify the cause of raised intraocular pressure.
- Determine (after mydriasis) whether a lesion behind the iris is solid or cystic.
- Find a small, retinal angioma.
- Determine the anterior extent of a pre-equatorial tumour.
- Measure the circumferential extent of ciliary body or angle involvement by a tumour, aligning in turn each lateral tumour margin with the centre of the mirror.



Gonioscopy showing tumour spread around the angle

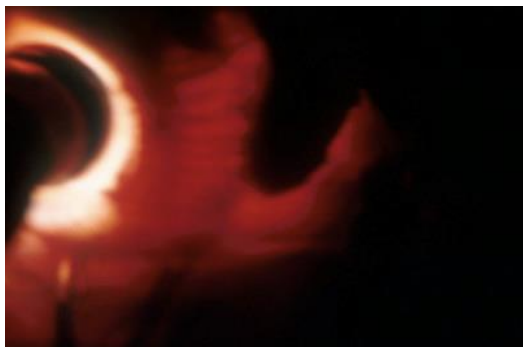TRANSILLUMINATION

- **Trans-pupillary**, placing the illuminator on the cornea. Care is taken not to over-estimate posterior extension because of a shadow cast by a thick tumour when the light is shone obliquely. If a transilluminator

is not available, the examiner can assess translucency while an assistant shines a light through the pupil with a binocular indirect ophthalmoscope and lens.

- **Trans-ocular**, with a right-angled transilluminator on the globe directly opposite to the tumour. This is less convenient than trans-pupillary transillumination, but slightly more accurate.
- **Trans-scleral**, with the light source on the sclera over the tumour. This only determines whether the tumour transmits light.

Not all pigmented tumours are melanomas and not all melanomas are pigmented.



Transpupillary transillumination showing the shadow of a choroidal melanoma extending to ora serrata

COLOUR PHOTOGRAPHY

[Colour photography](#) is useful for:

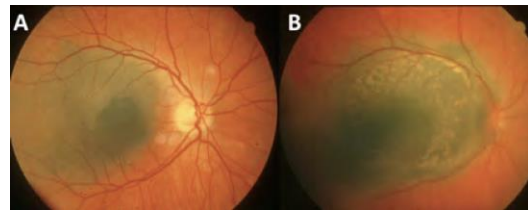
- Documenting the tumour size and its distances from optic disc and fovea (e.g., in disc diameters). This information is particularly useful when the tumour shows diffuse spread that is not adequately defined with ultrasonography (see below).
- Documenting the circumferential location of the tumour with respect to fovea. This is useful when preparing a 3-D model of the eye for planning radiotherapy.

Colour photography helps to determine whether the tumour is growing, for example, when differentiating naevus from melanoma or to detect marginal tumour recurrence after conservative therapy.

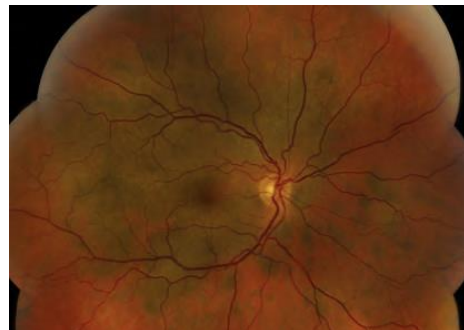The relationship between tumour margins and adjacent retinal vessels is noted, taking into consideration any variation in magnification and illumination.

When photographing extraocular tumours, the angle of illumination is adjusted to highlight any surface features of the tumour. When an iris lesion is photographed, care is taken to avoid corneal reflections over the lesion.

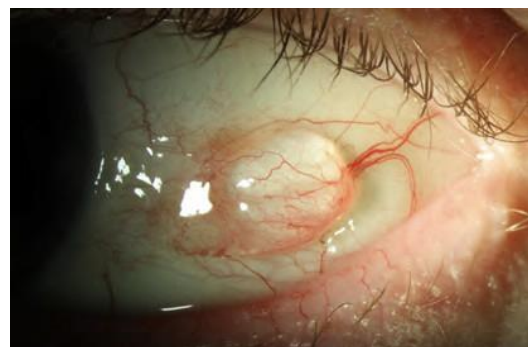
All patients should, if possible, be asked to sign a consent form for the use of their images for teaching, research, and audit purposes and for publication in journals and on the Internet. If the face is photographed so that the patient is identifiable, special consent is required.



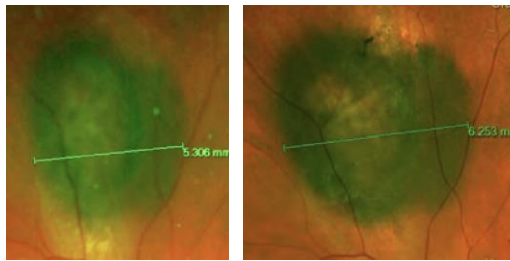
Choroidal melanoma in the right eye (A) at presentation, and (B) three years later, when the tumour had grown to involve the optic nerve. Unfortunately, the patient had got lost to follow-up at her hospital. Note the lateral extension across blood vessels and the increased lipofuscin.



Choroidal metastases from cutaneous melanoma. The tumours were too thin and diffuse for assessment by ultrasonography



Conjunctival cyst, best demonstrated by oblique illumination.



Sequential measurement of this tumour with the camera's callipers suggests an increase in transverse basal diameter from 5.3 mm to 6.3 mm, but this is a false impression caused by photographic artifact, as revealed by unchanged distances between the tumour margins and the retinal blood vessels.

FUNDUS AUTOFLUORESCENCE (FAF)

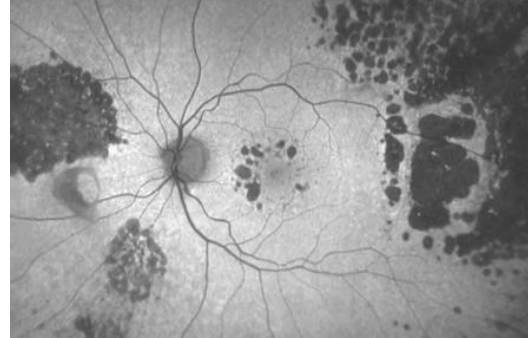
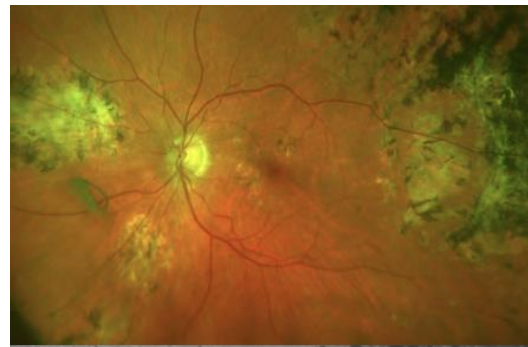
[Fundus autofluorescence](#) imaging helps to identify abnormalities that may not be visible with colour photography.

Hyper-autofluorescent abnormalities include lipofuscin, hemosiderin, subretinal lymphomatous deposits, and RPE/outer retinal damage caused by serous retinal detachment, which may be intermittent.

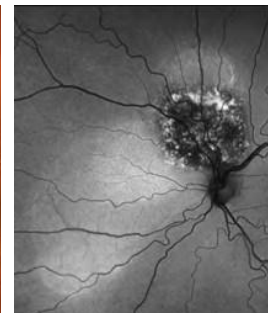
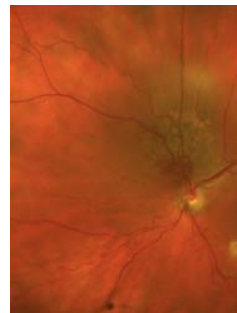
Hypo-autofluorescent abnormalities include RPE atrophy over a choroidal tumour - as well as RPE and choroidal atrophy exposing sclera.

FAF is especially useful for distinguishing choroidal naevi from small melanomas according to the amount of lipofuscin on the tumour surface. Lipofuscin can develop also over other kinds of tumour, such as metastases and haemangiomas.

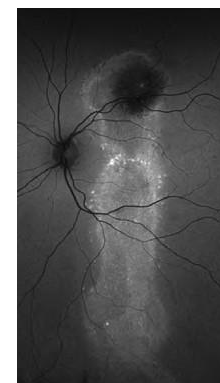
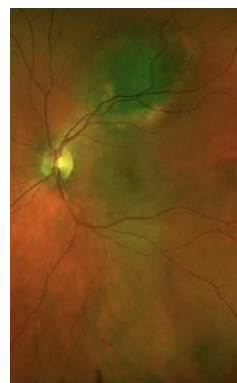
FAF is also useful for assessing activity in eyes with vitreoretinal lymphoma.



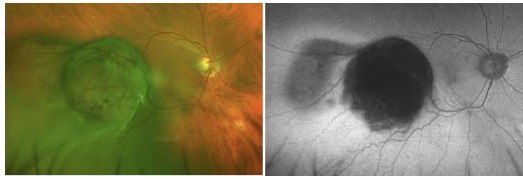
Retinal lymphoma with fine hyper-autofluorescent sub-RPE tumour deposits and hypo-autofluorescent areas of RPE atrophy



Choroidal melanoma with hyper-autofluorescent lipofuscin and RPE abnormality



Hyper-autofluorescence caused by fluid leakage from a small choroidal melanoma. Note also the brightly hyper autofluorescent lipofuscin that has desquamated from the tumour to settle inferiorly.



Mushroom melanoma, with hypo-autofluorescence where tumour has broken through RPE

FLUORESCIN ANGIOGRAPHY

[Tumour fluorescence](#) is related to:

- Fluorescein concentration in the tumour stroma.
- Hyperfluorescent RPE abnormalities, such as drusen, RPE detachments, choroidal new vessels and serous retinal detachment.
- Intervening hypofluorescent pigments, which include
 - (a) melanin in the tumour and RPE; (b) haemoglobin in any haemorrhages; and (c) lipofuscin (i.e., 'orange pigment').
- Reflections from white tissue, such as exposed sclera.
- Autofluorescence, which occurs with optic disc drusen.

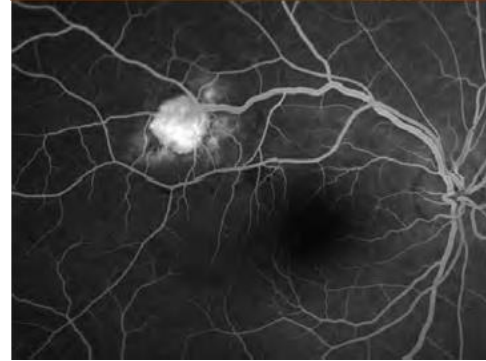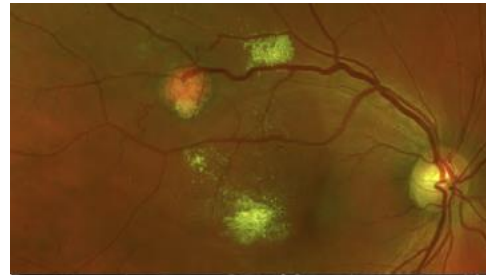
Fluorescence does not indicate whether a lesion is benign or malignant.

Hypofluorescence after phototherapy or radiotherapy of a choroidal melanoma does not necessarily mean that the tumour is destroyed.

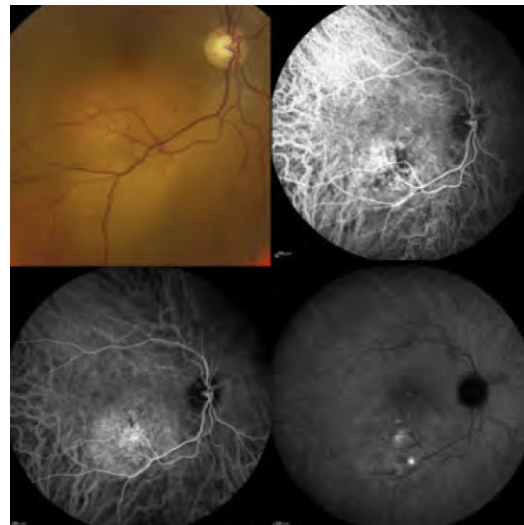[Fluorescein angiography is most useful when investigating retinal vascular tumours](#) and ocular neovascular complications.

INDOCYANINE-GREEN ANGIOGRAPHY (ICG)

The principles of fluorescein angiography apply to [indocyanine green angiography](#) (ICG), except that the infra-red light is not absorbed by melanin and haemoglobin to the same extent as fluorescein, so that changes in the RPE and retina are less conspicuous and so that choroidal vasculature is visible. Although choroidal haemangiomas show typical features on ICG angiography this investigation is not usually necessary because the ophthalmoscopic appearances are so characteristic.



Retinal hemangioblastoma, showing hyperfluorescence on fluorescein angiography



ICG angiogram of a choroidal haemangioma. Typically, choroidal haemangiomas show hypo fluorescence ('washout') in the late stages of the angiogram, but this feature is not always present, as in this case.

OPTICAL COHERENCE TOMOGRAPHY (OCT)

[Optical coherence tomography](#) demonstrates abnormalities such as cystoid oedema, retinal detachment, drusen, lipofuscin, and RPE detachment and atrophy.

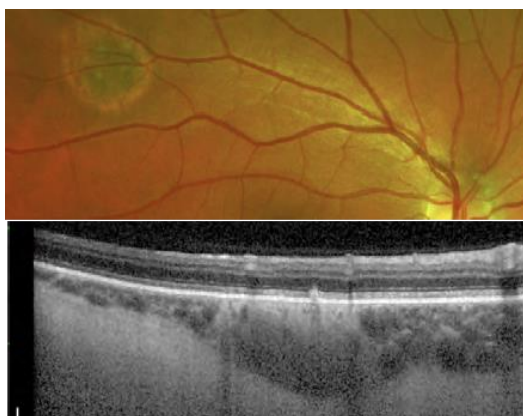
This investigation can also provide diagnostic clues (e.g., choroidal metastases and

lymphomas as well as posterior scleritis tend to have a lumpy surface not usually seen with other lesions.

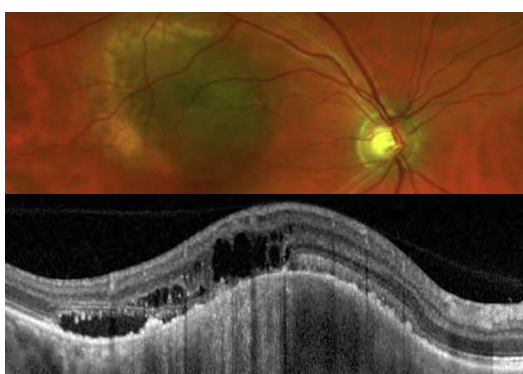
OCT is also useful for measuring thickness of small, posterior tumours, if the appropriate type of scan is performed (e.g., enhanced depth imaging).

[Anterior segment OCT](#) can help define iris and conjunctival lesions.

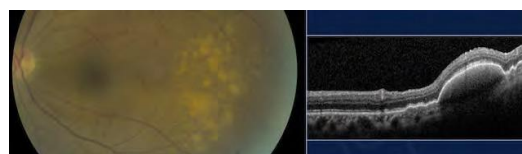
[OCT angiography](#) reveals radiation-vasculopathy providing information that can help predict response to anti-angiogenic agents in patients with macular oedema after radiotherapy.



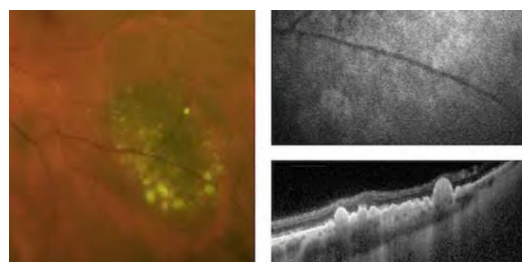
OCT showing a halo choroidal naevus with a flat anterior surface but with a convex posterior surface.



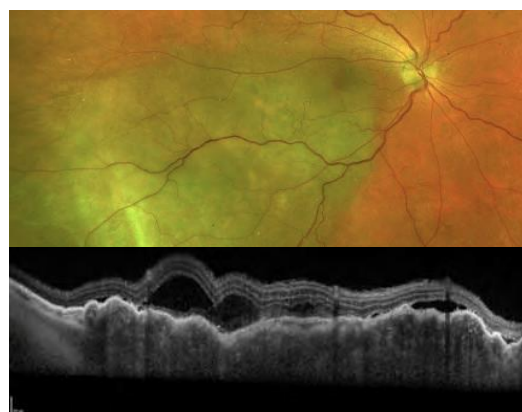
OCT showing intra-retinal oedema (a sign of chronicity) and sub-retinal fluid, as well as clumps of orange pigment on the anterior RPE surface over a choroidal melanoma



OCT showing sub-RPE deposits of lymphoma cells, trapped by Bruch's membrane.



Drusen overlying a choroidal naevus. (Top left) Colour photograph showing discrete, pearly-white drusen, (Top right) FAF showing minimal fluorescence, and (Bottom right) OCT showing sub-RPE location of drusen, which helps differentiate these from lipofuscin, which is on the retinal surface of the RPE



OCT showing the lumpy surface (typical of a choroidal metastasis), also with retinal detachment

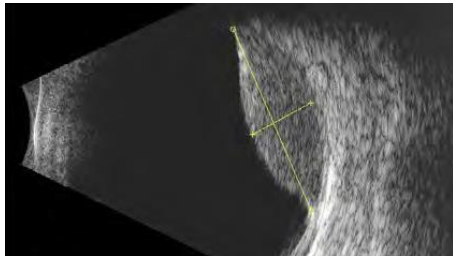
ULTRASONOGRAPHY (US)

Ultrasonography is performed to:

- Detect an intraocular tumour when the media are opaque, for example, in the presence of vitreous haemorrhage or cataract.
- Detect posterior extraocular tumour extension.
- Define the shape of the tumour (i.e., dome, diffuse, multilobular or mushroom). A mushroom shape is almost pathognomonic of uveal melanoma.
- Measure tumour dimensions (e.g., when planning therapy or assessing tumour growth or regression over time).

Ultrasonography is not useful for monitoring small tumours, because colour photography and OCT are usually more sensitive.

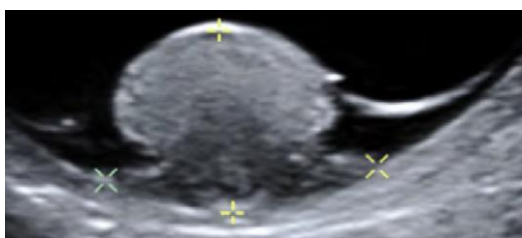
- Demonstrate internal acoustic reflectivity, which may suggest a particular diagnosis.



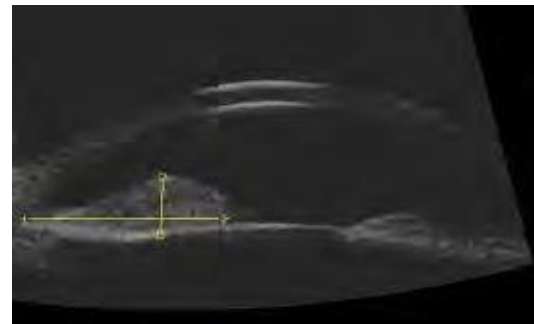
Transverse B-scan of a temporal choroidal melanoma in the right eye, taken with the patient looking to the right

The types of ultrasonography include:

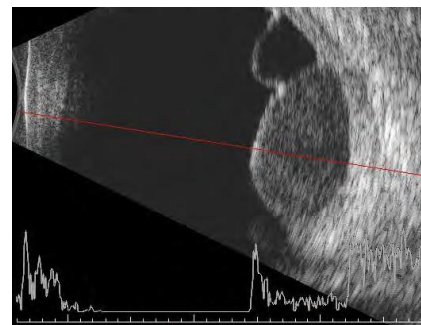
- [A-scan ultrasonography](#), with a stationary transducer, which produces a parallel, one-dimensional beam. Standardised ultrasonography uses an 8 MHz probe, calibrated with a model eye.
- [B-scan ultrasonography](#), performed with an oscillating transducer, which produces a two-dimensional beam focused near the retina.
- [High-frequency ultrasonography](#), also called 'ultrasound biomicroscopy', which defines structures anterior to the ora serrata.
- [Doppler ultrasonography](#), which demonstrates blood flow (e.g., helping to distinguish tumour from haemorrhage).
- Three-dimensional imaging, which can enhance tumour volume measurements.



B-scan ultrasound showing a choroidal tumour with a mushroom shape, which is almost pathognomonic of melanoma. Note the high reflectivity in the oedematous intra-retinal part of the tumour and the low reflectivity in the compact, intra-choroidal part of the lesion.



High-frequency scan of an iris melanoma.



A- and B-scans of a choroidal tumour

METHODS:

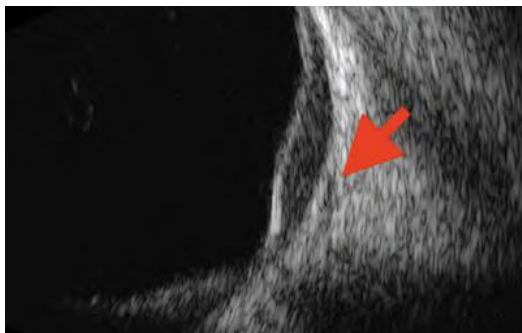Scans are longitudinal, transverse, oblique, and axial, obtained by tilting, sliding and twisting the probe.

- When searching for a tumour (e.g., with opaque media) start at the macula, with the probe touching the limbus, then slide the probe tip to the equator of the eye while tilting it to screen the eye as far anteriorly as ciliary body. Do this in all cardinal directions of gaze, with longitudinal and transverse scans.
- To scan an eccentric tumour, ask the patient to look in the direction of the tumour (e.g., to the left if the lesion is located temporally in the left eye). This is so that the probe is perpendicular to the tumour, making the internal scleral surface visible.
- Reduce the gain as much as possible, to improve resolution.
- When measuring tumour thickness, ensure that the probe is at right angles to the tumour, that the thickest point is measured, and that the callipers are placed at the internal scleral surface and tumour apex, taking account of any retinal detachment.
- Measure the largest, longitudinal, and transverse basal dimensions. Take care not to over-estimate tumour size in the presence of retinal detachment and not to

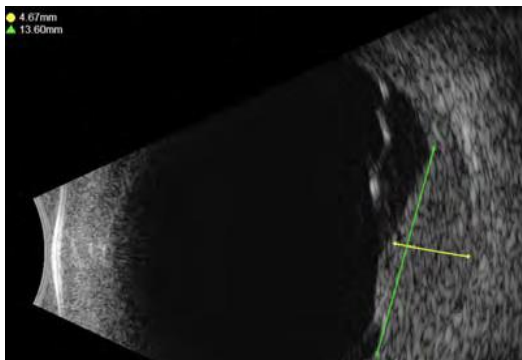
under-estimate basal diameter if the tumour margins are tapering.

- Assess internal tumour spread (e.g., from choroid to retina and vitreous).
- Look for extraocular tumour spread, taking care to differentiate tumour from muscle.
- Assess internal acoustic reflectivity noting whether the reflectivity is low, medium or high (compared to retro-ocular fat) and regular or irregular. It is useful to identify spontaneous movement (e.g., shimmering caused by blood flow).
- Look for echo mobility by asking the patient to look from side to side as the scan is taken.
- Assess the vitreous, by increasing the gain.
- Document the eye whether the scan is longitudinal, transverse or oblique.

When comparing sequential measurements, consider measurement variation and look for a trend over several weeks or months before deciding whether the tumour is growing or regressing. As a general principle, thickness must change by more than 0.5 mm to be significant.



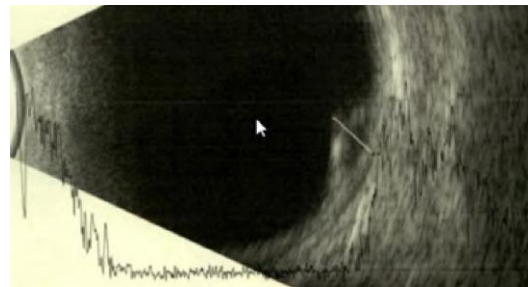
Extraocular extension of a choroidal lymphoma. Note the low internal acoustic reflectivity, which helps distinguish this tumour from diffuse choroidal haemangioma



B-scan of a choroidal haemangioma, showing a high internal acoustic reflectivity



B-scan of a choroidal metastasis, showing a moderate internal acoustic reflectivity



Exaggerated measurement of tumour thickness in a B-scan, because the referring ophthalmologist has included the sclera and retina in the measurement.

TUMOUR BIOPSY

The indications for [biopsy](#) are to:

- Establish the diagnosis if ocular examination and imaging are inconclusive (e.g., to differentiate between amelanotic choroidal melanoma and metastasis or between conjunctival squamous or sebaceous gland carcinoma and melanoma).
- Confirm the suspected diagnosis if requested by the patient (e.g., if treatment of a small, juxtapapillary choroidal melanoma is likely to cause severe visual loss). Some oncologists and radiotherapists insist on histological proof before starting treatment (e.g., vitreoretinal lymphoma, solitary intraocular metastasis without any evidence of other systemic disease).
- Characterise the type of uveal metastasis, in the absence of any detectable systemic primary tumour, so that investigations can be targeted accordingly.
- Detect genetic abnormalities related to metastatic spread from uveal melanoma (e.g., *BAP1* immunohistochemistry).
- Determine the severity of atypia in primary acquired melanosis, to decide whether to administer topical chemotherapy.
- Define the depth of invasion of a conjunctival tumour (e.g., melanoma), to

decide whether adjunctive radiotherapy is needed.

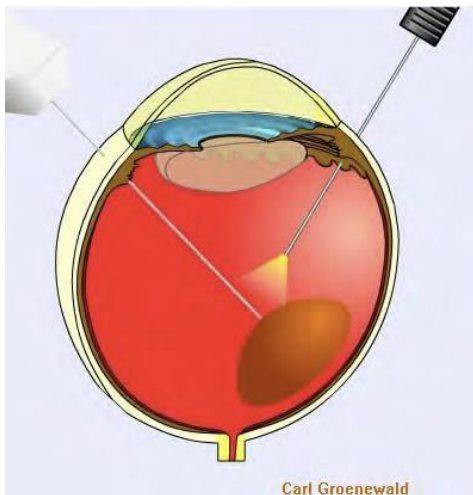
- Detect regional metastases in patients with high- risk conjunctival tumours, by performing sentinel lymph node biopsy.

Biopsy is contra-indicated in eyes with suspected retinoblastoma, because of a high risk of seeding tumour cells into the orbit.

EXCISIONAL BIOPSY

This is the preferred technique for any nodular conjunctival tumours. A no-touch technique is used. The instruments are replaced with a fresh set for wound closure, to prevent tumour seeding. Care is taken not to cause crush artefact.

Excisional biopsy is also useful for some uveal tumours if tumour removal is likely to be an effective treatment irrespective of the diagnosis (e.g., when it is not possible to differentiate between ciliary body melanoma, adenocarcinoma, neurilemmoma, etc.).



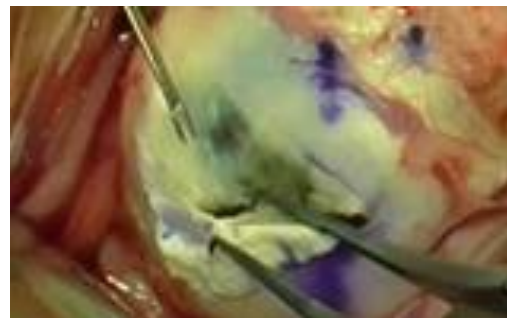
Trans-retinal aspiration biopsy of a choroidal tumour with a vitreous cutter

INCISIONAL BIOPSY

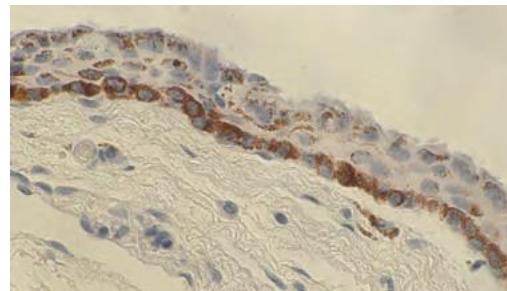
This is indicated for diffuse conjunctival disease, such as primary acquired melanosis (PAM), both at initial presentation and, if recurrence is suspected, after treatment. Incisional biopsy of nodular tumours, such as melanoma, is contra-indicated because this procedure can seed tumour cells to adjacent tissues, giving rise to multiple recurrences, which may be difficult or

impossible to control, except by exenteration. Care is taken not to cause crush artefact.

[Incisional biopsy of uveal tumours](#), ideally with Essen Forceps, can be performed under a lamellar scleral flap, using tissue glue to seal the wound to prevent extraocular recurrence.



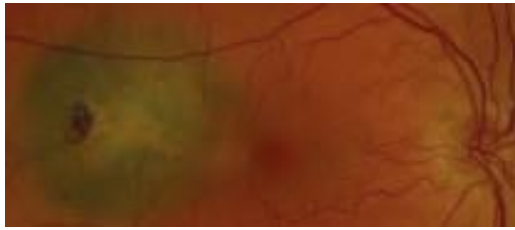
Trans-scleral tumour biopsy with Essen Forceps



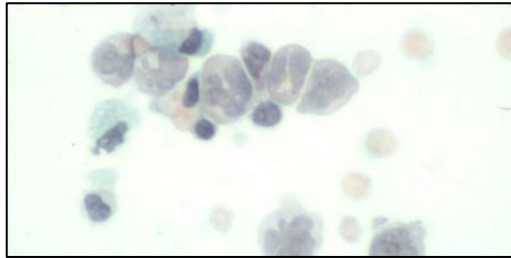
Incisional conjunctival biopsy showing an increased number of melanocytes. These show no cellular features of malignancy (i.e., no 'atypia') and are not invading the superficial layers of the epithelium. This biopsy made it possible to discharge the patient without any topical chemotherapy

ASPIRATION BIOPSY

Fine-needle aspiration biopsy of intraocular tumours is performed trans-sclerally or trans-retinally, depending on the location of the lesion. The use of a vitreous cutter provides larger samples and in some centres is performed without vitrectomy, laser or tamponade. Suspected vitreoretinal lymphoma requires a large, undiluted sample of vitreous and rapid transfer to the laboratory unless a transport medium is used.



Choroidal melanoma, confirmed by trans-retinal biopsy with a vitreous cutter



Vitreous biopsy showing lymphoma cells with large, multilobular nuclei

The main risks are vitreous haemorrhage, which usually resolves spontaneously, and failure to achieve a result, because of an insufficient sample or technical difficulties in the laboratory. Subconjunctival seeding of uveal melanoma can rarely occur unless cryotherapy is administered. Biopsy is not believed to cause metastasis of uveal melanoma.

CONJUNCTIVAL IMPRINT CYTOLOGY

This does not provide information about the depth of tumour spread and is not widely used.

LIQUID BIOPSY

Research is in progress to analyse blood samples (i.e., '[liquid biopsy](#)') instead of tumour tissue specimens (e.g., to detect circulating DNA predicting metastasis from uveal melanoma).

It is essential to liaise with the laboratory in advance of any biopsy to ensure that the correct transport medium is used. This is especially important with vitreoretinal lymphoma, because of the need to process the sample without delay.

In [patients with retinoblastoma](#), analysis of cell free DNA in aqueous humour can identify the causative RB1 mutation as well as secondary

genetic aberrations that are associated with ocular and systemic prognosis. This is especially useful when tumour tissue is not available because the patient has not undergone enucleation.

[Protein biomarkers in aqueous humour from eyes with uveal melanoma](#) can differentiate this condition from other conditions and indicate the risk of metastatic disease.

COMPUTERISED TOMOGRAPHY (CT)

The indications for CT are limited as far as uveal tumours are concerned, because US is usually adequate. For example, although CT nicely demonstrates bone in a choroidal osteoma, similar information can be obtained less expensively and more conveniently with US.

MAGNETIC RESONANCE IMAGING (MRI)

Magnetic resonance imaging with fat suppression and contrast agent can be useful in selected cases.

Melanin has peculiar paramagnetic features, being hyperintense and hypointense with respect to vitreous in T1 and T2 images respectively; however, as mentioned, not all melanocytic tumours are melanoma and not all melanomas are pigmented.

With conjunctival tumours, MRI scans may detect or define orbital spread. Some find contrast-enhanced MRI useful in differentiating eccentric disciform from melanoma.

OCULAR TUMOURS

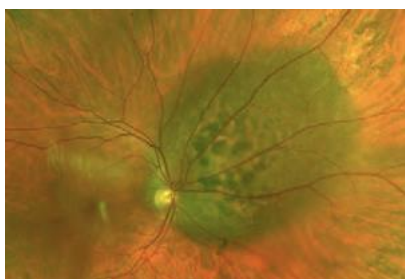
UVEAL MELANOMA

About 90% of all [uveal melanomas](#) involve the choroid, the remainder being confined to ciliary body and/or iris. Presentation peaks at around the age of 60 years and is rare before adulthood. Men and women are affected in similar numbers.

CLINICAL FEATURES

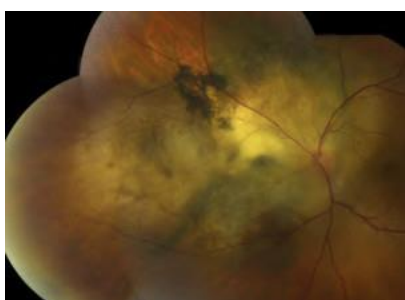
Choroidal melanoma

- Dome shape in most patients, with brown/grey colour from multilayering of the RPE, which can also show drusen and clumps of lipofuscin. This pigment appears orange over pigmented tumours and brown over amelanotic tumours. Where the RPE is absent, the tumour itself is white, yellow, tan, brown, grey or black, with visible blood vessels if the tumour is amelanotic.



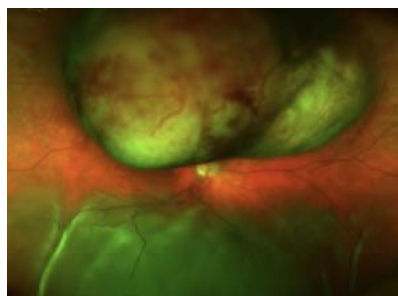
Choroidal melanoma involving disc

- Mushroom shape, if the tumour has grown through RPE and Bruch's membrane, which strangulates the tumour veins, causing oedema and tissue swelling.
- Diffuse growth if the tumour is infiltrative, often with extraocular extension by the time the diagnosis is made.



Diffuse choroidal melanoma

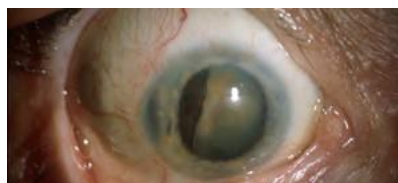- Exudative retinal detachment, initially only over the tumour surface, eventually becoming total.



Large, amelanotic choroidal melanoma with bullous serous detachment

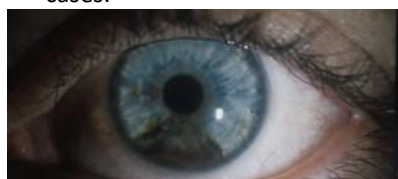
Ciliary body melanoma

- The tumour can have a dome shape or can grow circumferentially. It can be pigmented or amelanotic.
- The overlying episcleral vessels are usually dilated ('sentinel vessels').



Ciliary body melanoma invading anterior chamber. Note the sentinel vessels.

- As with choroidal tumours, ciliary body melanomas can cause retinal detachment.
- Pressure on the lens can cause astigmatism and cataract.
- The tumour can spread into the anterior chamber or extraocularly to appear under the conjunctiva.
- The tumour can be nodular or diffuse and pigmented or amelanotic.
- Almost all are inferior.
- Spread around the angle can cause glaucoma. Gonioscopy is required in all cases.



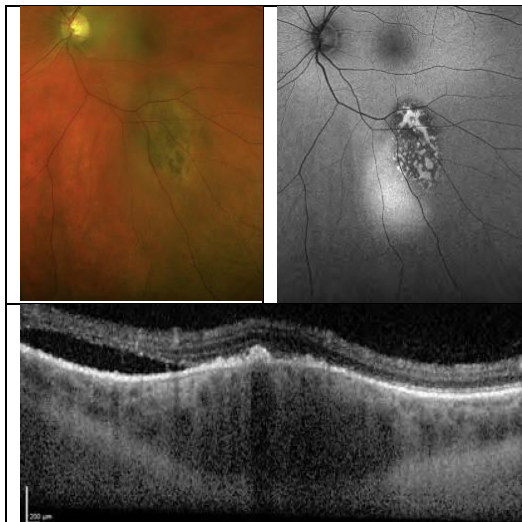
Iris melanoma

CLINICAL INVESTIGATIONS

[Imaging of uveal melanoma](#) has advanced greatly in recent years.

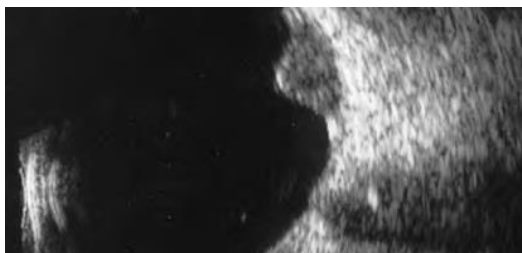Choroidal melanoma

- Fluorescein angiography does not usually assist diagnosis.
- Autofluorescence imaging shows hyper-autofluorescent lipofuscin and hypo-autofluorescence where the RPE is absent.
- Optical coherence tomography reveals serous retinal detachment and intra-retinal oedema; measures thickness more accurately than ultrasound in small tumours; and helps distinguish drusen from lipofuscin.



Inferior choroidal melanoma in the left eye with orange pigment on its surface. Autofluorescence imaging shows hyper-autofluorescent lipofuscin. OCT shows the tumour, with subretinal fluid and clumps of lipofuscin on the retinal side of the RPE. OCT also indicates the tumour thickness.

- Ultrasonography shows the tumour shape (i.e., dome, mushroom or diffuse) and reveals any extraocular spread (which must not be confused with oblique muscle). The internal acoustic reflectivity is low, except for tumour that has grown through RPE.

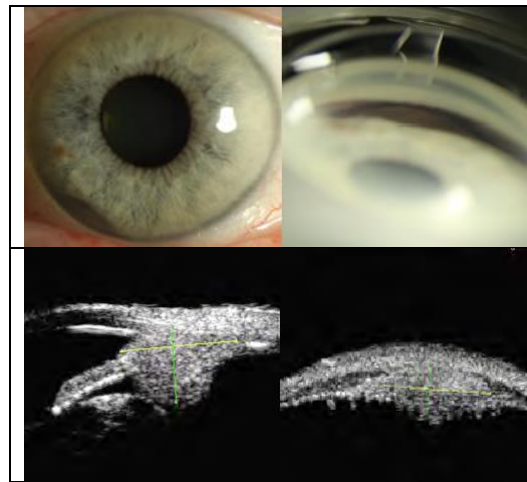


B-scan ultrasound of a choroidal melanoma showing low acoustic reflectivity

- Indocyanine green angiography, computerised tomography, and magnetic resonance imaging are rarely required.
- Trans-scleral or trans-retinal biopsy is useful when the diagnosis is uncertain.

Ciliary body melanoma

- Transillumination shows the circumferential extent of the tumour.
- Ultrasonography can reveal small ciliary body melanomas that are not visible by ophthalmoscopy, even with mydriasis. High-frequency ultrasonography may be needed.
- Gonioscopy is useful to exclude anterior chamber spread.



Ciliary body melanoma invading anterior chamber, defined with slit-lamp photograph, gonioscopy, and longitudinal and transverse ultrasound B-scans

- If diagnostic biopsy is necessary, this can be done trans-sclerally, either with a fine needle or with Essen Forceps, under a lamellar scleral flap.

Iris melanoma

- High-frequency ultrasonography is useful for measuring tumour dimensions and excluding ciliary body involvement.
- Incisional biopsy may differentiate melanoma from naevus in some cases.

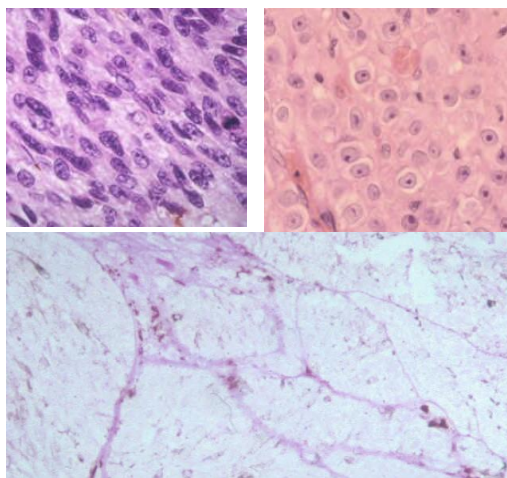
LABORATORY INVESTIGATIONS

Histopathology

- The melanoma cell type can be spindle, epithelioid, or mixed. Epithelioid cells are associated with an increased risk of metastasis.
- When the entire tumour is available for analysis (e.g., after enucleation or local

resection) the mitoses per high-power field indicates of tumour growth rate and risk of metastasis.

- Extravascular matrix in the tumour stroma can form a variety of patterns, such as closed loops, which indicate a worse prognosis.
- Immunohistochemistry using stains such as Melan-A confirms the diagnosis of melanoma. Recently, nuclear *BAP1* staining has been found to be a useful prognostic tool, with nuclear *BAP1* loss associated with metastasis.



Light micrographs of choroidal melanomas showing spindle and epithelioid melanoma cells and closed loops

Genetic aberrations

[Genetic analysis](#) of uveal melanoma has greatly enhanced survival prognostication.

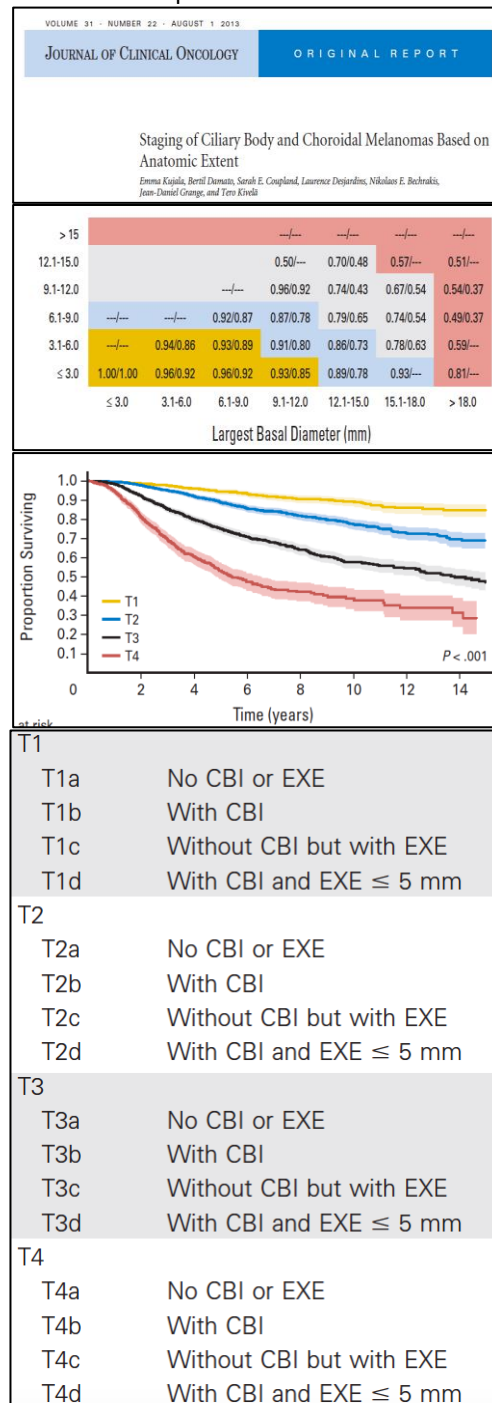
- Metastatic disease develops almost exclusively in patients whose uveal melanoma shows chromosome 3 loss ('monosomy 3'), especially with 8q gain.
- Uveal melanomas have been categorised into [four genetic subgroups](#), according to chromosomes 3 and 8 abnormalities and other genetic aberrations.
- 6p gain and *EIF1AX* mutation are associated with a better prognosis.
- *BAP1* and *SF3B1* mutations indicate a high risk of metastasis.
- In the US, uveal melanomas are classified according to their gene expression profile, with class 2 tumours having a worse prognosis.

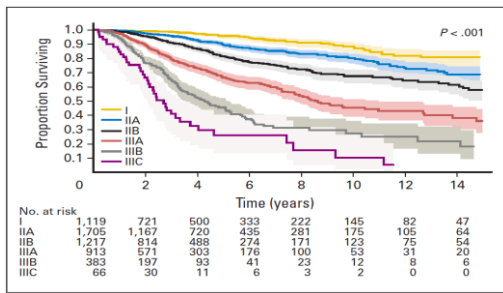
Patients who are young or who have a family history of uveal melanoma, skin melanoma, renal cancer or mesothelioma are referred to a

geneticist to exclude the *BAP1* tumour predisposition syndrome.

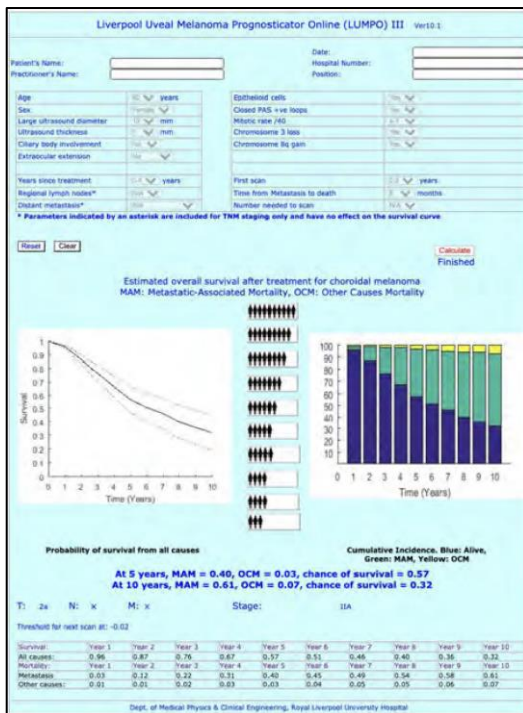
Survival prognostication

- The [tumour, Node, Metastasis \(TNM\) staging](#) system predicts metastatic death according to tumour thickness, basal diameter, ciliary body involvement and extraocular spread.





- [The Liverpool Uveal Melanoma Prognosticator Online \(LUMPO\)](http://www.LUMPO.net) (www.LUMPO.net), developed by Damato and associates in Liverpool, predicts survival according to the TNM predictors as well as melanoma cell type, mitotic count, extravascular matrix patterns, chromosome 3 loss, and chromosome 8q gain, also taking into account the patient's age and sex.



LUMPO screenshot, showing survival plots, TNM stage, and estimates of metastatic and non-metastatic mortality. (Currently not available in Europe until a CE Mark is obtained)

- Gill et al have report good prognostic results with a score determined by sex, age, TNM stage, chromosome 3 loss and 8q gain.
- Damato et al have also developed [tables predicting metastatic death](#) according to tumour diameter, chromosome 3 loss and age.

A				B			
DISOMY-3 MELANOMA							
LBDT [mm]	Treatment age <81 yrs			Treatment age >80 yrs			LBDT [mm]
	Years after treatment						
	2	5	10	2	5	10	
<10.1	0.1 [0, 0.5]	0.7 [0, 1.6]	2.1 [0.7, 4]	<10.1	0.1 [0, 0.5]	0.6 [0, 1.4]	1.4 [0.4, 2.6]
10.1-12.0	0.8 [0.2, 1.7]	1.7 [0.5, 3.4]	3.7 [1.5, 6.7]	10.1-12.0	0.7 [0.1, 1.6]	1.5 [0.5, 3]	2.7 [1.1, 4.8]
12.1-14.0	1.1 [0, 2.5]	3.3 [1, 6]	6.5 [2.7, 11]	12.1-14.0	1 [0, 2.4]	2.5 [0.9, 5.3]	4.9 [2, 8.3]
14.1-16.0	1.5 [0, 4]	5.3 [1.8, 9.6]	11 [4.9, 18]	14.1-16.0	1.5 [0, 3.8]	4.6 [1.6, 8.4]	8 [3.7, 13]
16.1-18.0	3.1 [0, 8.7]	12 [5.1, 21]	17 [8, 28]	16.1-18.0	2.9 [0, 8.3]	11 [4.5, 19]	14 [6.5, 22]
18.1-28.0	6 [0, 14]	12 [2.4, 25]	18 [6.2, 32]	18.1-28.0	5.7 [0, 14]	11 [2.3, 22]	15 [4.6, 26]

C				D			
MONOSOMY-3 MELANOMA							
LBDT [mm]	Treatment age <81 yrs			Treatment age >80 yrs			LBDT [mm]
	Years after treatment						
	2	5	10	2	5	10	
<10.1	2.5 [0.6, 5.2]	13 [6.4, 21]	26 [13, 41]	<10.1	2.4 [0.5, 5]	11 [5.5, 18]	19 [9.6, 30]
10.1-12.0	5 [2.2, 8.4]	37 [12, 28]	37 [22, 51]	10.1-12.0	5 [2.1, 8.1]	18 [11, 25]	28 [17, 38]
12.1-14.0	8 [4.9, 12]	33 [24, 42]	53 [38, 65]	12.1-14.0	7.9 [4.7, 12]	29 [21, 37]	42 [30, 51]
14.1-16.0	13 [9.2, 18]	42 [35, 50]	66 [55, 75]	14.1-16.0	13 [8.8, 17]	37 [30, 44]	52 [43, 60]
16.1-18.0	21 [16, 27]	59 [51, 67]	77 [67, 85]	16.1-18.0	20 [15, 26]	53 [46, 61]	64 [56, 71]
18.1-28.0	32 [26, 38]	70 [63, 78]	80 [73, 87]	18.1-28.0	31 [25, 37]	64 [57, 71]	71 [64, 77]

E				F			
UNKNOWN CHROMOSOME 3 STATUS							
LBDT [mm]	Treatment age <81 yrs			Treatment age >80 yrs			LBDT [mm]
	Years after treatment						
	2	5	10	2	5	10	
<10.1	0.6 [0.2, 1.1]	3.1 [2.1, 4.2]	6.6 [5, 8.3]	<10.1	0.6 [0.2, 1]	2.7 [1.8, 3.6]	4.7 [3.6, 6]
10.1-12.0	2 [1.2, 3]	7 [5.3, 8.9]	13 [10, 15]	10.1-12.0	1.9 [1.1, 2.9]	6.1 [4.6, 7.8]	9.7 [7.8, 12]
12.1-14.0	4 [2.6, 5.4]	15 [13, 18]	25 [21, 28]	12.1-14.0	3.8 [2.5, 5.1]	14 [11, 16]	19 [17, 22]
14.1-16.0	19 [5.7, 10]	25 [22, 30]	47 [36, 45]	14.1-16.0	19 [5.5, 9.8]	22 [19, 26]	41 [28, 36]
16.1-18.0	15 [11, 19]	43 [37, 48]	55 [50, 61]	16.1-18.0	14 [11, 18]	38 [33, 43]	46 [41, 51]
18.1-28.0	25 [21, 30]	56 [50, 62]	65 [59, 70]	18.1-28.0	24 [20, 29]	64 [45, 56]	71 [51, 62]

Damato B, Eleuteri A, Hussain R, Kalirai H, Thornton S, Taktak A, Heimann H, & Coupland SE. Parsimonious models for predicting mortality from choroidal melanoma. Invest Ophthalmol Vis Sci. 2020;0(0):28990. <https://doi.org/10.1167/iovs.0.0.28990>

If these methods are used and if arc basal tumour diameter has been reported, this needs to be converted to chord diameter. If the internal ocular diameter is 22 mm (i.e., excluding sclera) and if the arc basal tumour diameter is 20 mm, ask an AI program to 'convert an arc length of 20 mm to chord length if diameter of circle is 22 mm'. The answer will be 17.4 mm. In a 40-year-old woman with a 10-mm thick tumour, this would reduce the LUMPO-estimated 10-year metastatic risk from 46% to 29%.

TREATMENT

No treatment

A small choroidal melanoma may not grow for several years, if at all. [A recent study by Damato et al](#), using LUMPO, suggests that the risk of metastasis does not increase significantly if treatment is deferred until (minima) growth is observed. This approach may enable some patients to retain vision for months or years, perhaps avoiding treatment altogether.

Plaque Brachytherapy

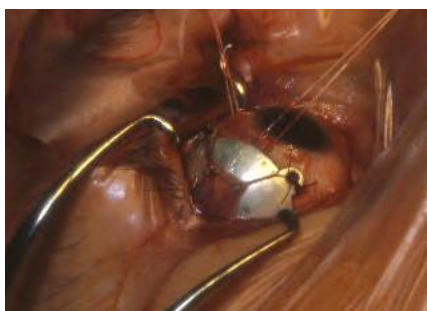In most centres, the first choice of treatment is [plaque radiotherapy](#) / [brachytherapy](#), which is

administered with a radioactive plaque containing ruthenium-106 or iodine-125, popular in Europe and the US respectively. Brachytherapy involves an operation to suture the plaque to the sclera over the tumour and a second operation, a few days later, to remove the plaque once the prescribed radiation dose has been delivered.

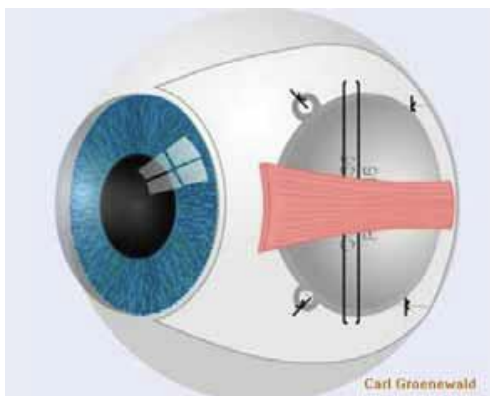
Iodine plaques emit gamma irradiation and can successfully treat tumours as thick as 10 mm; however, they deliver large doses of radiation to healthy ocular structures, such as the optic disc, causing collateral damage.

Our first choice of radiotherapy for choroidal melanomas up to 5 mm in thickness is ruthenium plaque radiotherapy.

To reduce collateral damage to optic disc and fovea, the plaque can be placed eccentrically, with its posterior edge close to the posterior tumour margin. This requires accurate plaque insertion, which can be achieved using a right-angled transilluminator and a perforated template, designed by Damato, produced by Altomed Ltd, UK., and distributed by Eckert and Ziegler, Germany.



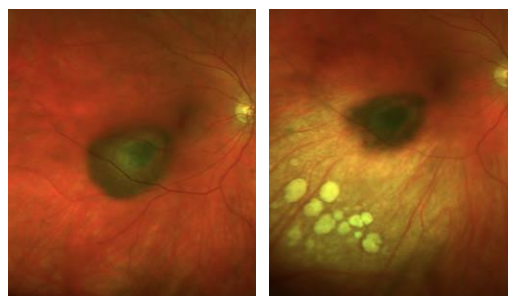
Ruthenium plaque placed over a temporal choroidal melanoma in the right eye, under the lateral rectus muscle.



Ruthenium plaque with mattress suture



Ruthenium plaque template and right-angled transilluminator (not to scale), designed by Damato and manufactured by Altomed, Boldon, UK. The surgeon places the tip of the transilluminator into the posterior perforation in the template and uses this to push the template posteriorly while performing binocular indirect ophthalmoscopy until the light of the transilluminator appears posterior to the tumour ('sunrise sign'). After suturing the template to the sclera, its position relative to the tumour is checked by sliding the tip of the transilluminator down the groove on the template until it clicks into the perforation, then confirming by binocular indirect ophthalmoscopy that the spot of light in relation to the tumour margin is where it should be ('sunset sign').



Choroidal melanoma before and after ruthenium plaque radiotherapy by Damato. The plaque was placed eccentrically, with its posterior edge aligned with the posterior tumour margin to conserve central vision. The treated tumour developed a dark, moth-eaten appearance. With a scleral dose of 350 Gy, the tumoricidal effects of the radiation extend about 2 mm beyond the visible area of choroidal atrophy.

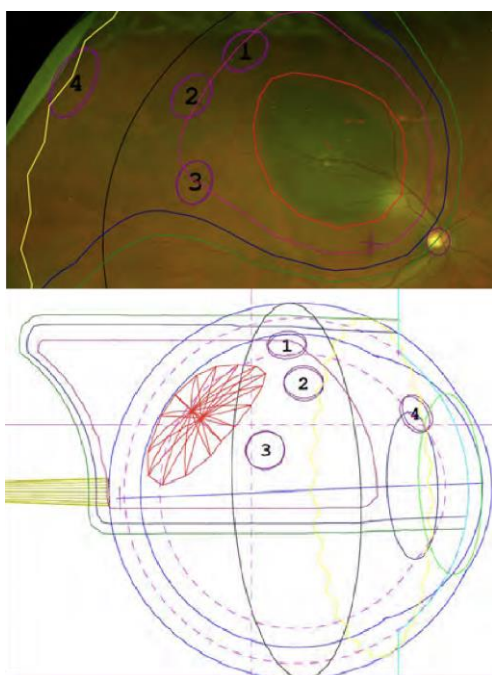
An Australian group reported a single case with globe salvage and vision preservation by [neoadjuvant darovasertib and crizotinib](#), which induced regression of a large choroidal melanoma so plaque radiotherapy was possible.

Proton beam radiotherapy

[Proton beam radiotherapy](#) enables a high dose of radiation to be aimed precisely at a uveal melanoma irrespective of the tumour's size, shape and location.

Facilities for this treatment are available in a growing number of centres around the world. Some oncologists use proton beam radiotherapy for all choroidal melanomas; others reserve it for tumours that cannot adequately be treated by brachytherapy, that is, tumours that are large or those that extend close to the optic disc or fovea.

The treatment involves (1) ultrasound measurements of tumour dimensions and distance from disc; (2) insertion of tantalum markers at known distances from tumour margins, from each other, and from limbus; (3) 3-D computer modelling of the eye and tumour, using the ultrasound and intra-operative measurements and x-rays of the tantalum markers; (4) preparation of a tight-fitting face mask and dental bite to immobilise the head during treatment; and (5) proton beam radiotherapy, delivered once a day over four consecutive days.



Fundus photo and computer-generated model showing the tumour, tantalum markers and dosimetry.

Proton beam radiotherapy of large uveal melanomas is often complicated by persistent exudative retinal detachment, rubeosis and neovascular glaucoma. This condition, which Damato has termed 'toxic tumour syndrome', can be treated successfully by treating the irradiated tumour with [photodynamic therapy](#), [transpupillary thermotherapy](#), [trans-retinal endoresection](#), [endodrainage](#) or [trans-scleral](#)

[exoresection](#). In some cases, this problem can be prevented by anti-angiogenic therapy.

Proton beam radiotherapy of medial tumours can cause permanent epiphora if the tear ducts are included in the radiation field. Irradiation of the superior eyelid margin results in keratinization of the superior tarsal conjunctiva and painful corneal abrasion. This problem can be avoided by '[trans-palpebral proton beam radiotherapy](#)' (i.e., through the closed eyelid), so that the lid margin is out of the radiation field.

In 1994, Damato and associates was found that [iris melanomas can be treated satisfactorily with proton beam radiotherapy](#), thereby avoiding the problems of iridectomy and iridocyclectomy. The main problems are cataract, which is eminently treatable, and dry eye. Glaucoma, limbal stem cell failure, and keratopathy can cause severe problems after [whole anterior segment irradiation](#), although symptoms can improve after a few months of treatment with lubricants.

Stereotactic radiotherapy

With [stereotactic radiotherapy](#), a highly collimated beam of radiation is aimed at the tumour from many different directions, either simultaneously or in sequence, so that a high dose of radiation is delivered to the melanoma with relative sparing of healthy tissues. This approach is generally used as an alternative to proton beam radiotherapy, in centres where a cyclotron unit is not available.

Photocoagulation

Photocoagulation of uveal melanoma with high-energy light is associated with a high complication rate and has been superseded by transpupillary thermotherapy.

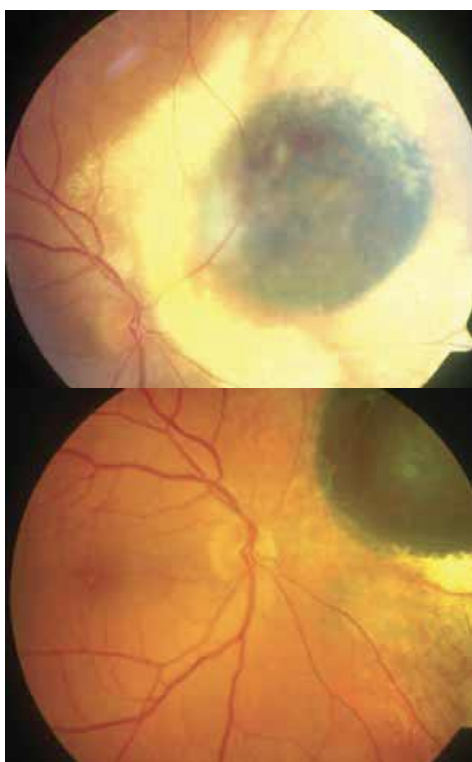Transpupillary thermotherapy (TTT)

With [transpupillary thermotherapy](#), the tumour is heated by a few degrees for about one minute by means of a 3 mm diode laser beam, administered using a contact lens. The power of the laser is adjusted so that retinal blanching does not develop for at least 40 seconds.

The effects of transpupillary thermotherapy are said to extend to a depth of up to 4 mm. Adjunctive brachytherapy is advocated as a means of avoiding local tumour recurrence from intra-scleral tumour (i.e., 'sandwich technique').

Transpupillary thermotherapy alone is associated with a high rate of local tumour recurrence and is not administered as a primary treatment for choroidal melanoma unless (1) the patient has a limited life expectancy, (2) the patient is diabetic (so that there is an increased risk of radiation retinopathy), has a small tumour and accepts that TTT is not as reliable as radiotherapy, or (3) the patient has an indeterminate melanocytic choroidal tumour but does not accept monitoring after being informed of uncertainty regarding the risks of such management.

We generally perform TTT only as a secondary treatment after radiotherapy (1) if there is uncertainty about adequacy of radiotherapy, or (2) as a treatment for exudation, either at the time of presentation or when exudation develops after treatment.



Exudation from an irradiated choroidal melanoma, with resolution after transpupillary thermotherapy of the 'toxic tumour'

TTT without adjunctive radiotherapy is associated with a significant risk of local tumour recurrence, which may extend extraocularly; these patients therefore require life-long monitoring, if possible, by their local ophthalmologist, with b-scan ultrasonography.

Photodynamic therapy (PDT)

[Photodynamic therapy using Verteporfin](#) is associated with a high failure rate. We

therefore reserve this modality for: (1) 'leaking naevi'; (2) exudation or macular oedema after radiotherapy; and (3) selected, small melanomas when other methods are likely to cause visual loss and when the patient accepts that radiotherapy may be required for persistent or recurrent tumour.

Aura biosciences has developed [AU-011 \(Bel-Sar\)](#), which is injected into the vitreous and which is activated by laser. At the time of writing this guide, the results of clinical trials are still awaited. (

Because of the risk of local tumour recurrence, life-long monitoring by an ophthalmologist is indicated, with b-scan ultrasonography to exclude extraocular spread.

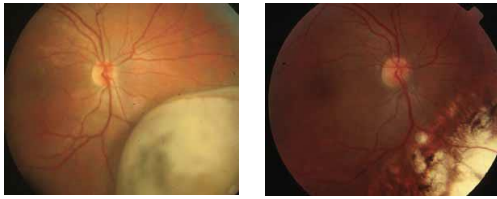
Cryotherapy

Cryotherapy has been reported to be effective for some choroidal melanomas; however, this form of therapy has not gained widespread acceptance.

Trans-Scleral Local Resection (Exoresection)

[Iridectomy](#) and [iridocyclectomy](#) for small, iris and ciliary body melanomas have been performed for many years. Advances in microsurgery and hypotensive anaesthesia have also made it possible to remove large tumours extending as far posteriorly as the fovea by [trans-scleral choroidectomy / exoresection](#). This operation is difficult and therefore performed only in a few centres, where it is reserved for tumours that are considered too large for radiotherapy.

The main complications are local tumour recurrence and rhegmatogenous retinal detachment. Tumour control has improved with adjunctive brachytherapy and by restricting this surgery to tumours less than 17 mm in diameter. Surgical refinements have reduced the incidence of retinal tears. In the event of a retinal break, immediate vitreoretinal surgery at the end of the local resection is highly successful at preventing retinal detachment.



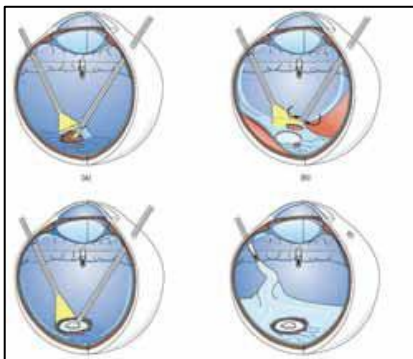
Choroidal melanoma (13 x 11 x 7 mm) before and after trans- scleral local resection by the author. Eighteen years post- operatively, the vision was 6/5 and there was no recurrence.

Endoresection

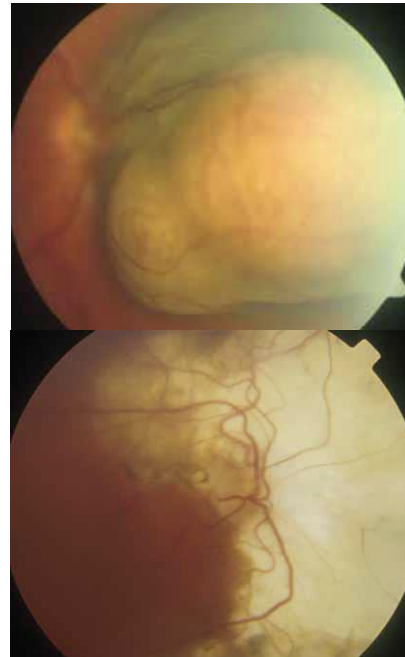
With [endoresection](#), the uveal melanoma is removed with a vitreous cutter, either through a hole in the retina or after raising a retinal flap. This is performed under heavy liquid. After tumour removal, endolaser is administered to kill any residual tumour and to achieve retinopexy. The eye is filled with silicone, which is removed after 12 weeks, when epiretinal membrane peel and phaco are performed, with lens implant.

Some administer neoadjuvant radiotherapy (i.e., before the endoresection and some prescribe adjuvant radiotherapy (i.e., after the endoresection.

Most complications have been caused by the vitrectomy (e.g., entry-site tears and not the endoresection itself. Following a fatal case of air embolism, fluid-air-silicone oil exchange was replaced by direct heavy liquid-silicone oil exchange but even this procedure has been followed by sudden deaths from [gas embolism](#) soon after the operation, probably caused by vaporisation of the heavy liquid, perfluoro- n-octane, when this enters the general circulation.



Endoresection of choroidal melanoma



Choroidal melanoma (11 x 10 x 7 mm) in the right eye of a 65-year-old man before and after endoresection by Damato. The vision in the left eye was poor because of trauma. Five years postoperatively the vision in the treated eye was 6/9 and there was no recurrence

Enucleation

Primary enucleation for uveal melanoma is now performed only when other methods are considered unlikely to conserve the eye and useful vision.

The enucleation is performed in the standard fashion, using the surgeon's preferred implant. Non-porous implants give the same results as porous implants but are less expensive and easier to remove if they become exposed. To ensure that the correct eye is removed, the tumour is visualised by binocular indirect ophthalmoscopy, which is done *after* draping the patient and covering the other eye, in accordance with WHO standards.

Studies by Damato and associates show that [quality of life after enucleation](#) is not significantly worse than after radiotherapy if the visual acuity in the fellow eye is good. Poor quality of life occurs only in about 20% of patients, in whom loss of well-being is caused by factors unrelated to the ocular tumour or its treatment (e.g., poor social support, poor general health, financial difficulties, etc.)

Iris melanomas

Treatment by iridocyclectomy has largely been replaced by plaque brachytherapy or proton beam radiotherapy.

OCULAR RESULTS OF CONSERVATIVE THERAPY

The ocular results of conservative therapy are usually reported in terms of local tumour control, visual acuity, ocular conservation and complications such as exudative or rhegmatogenous retinal detachment, neovascular glaucoma, cataract and phthisis.

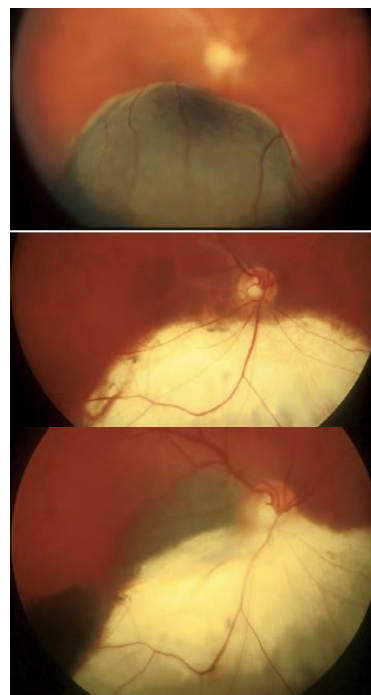
Clinical features predicting ocular outcomes include>

- Largest basal tumour diameter.
- Tumour thickness.
- Distances to optic disc and fovea.
- Retinal invasion.
- Extra-ocular spread.
- Exudative retinal detachment.
- Systemic factors such as diabetes, which aggravate visual outcome after radiotherapy.
- The degree of tumour malignancy, as indicated by cell type and mitotic count, which is important but not usually known at the time of primary treatment.
- It is not known whether genetic aberrations influence ocular outcome; however, if genetic predictors of metastasis are known to be present (e.g., if biopsy has been performed before treatment), then more aggressive therapy may be administered (e.g., selecting radiotherapy instead of photodynamic therapy). This would avoid patients or their relatives attributing any metastatic disease on any failure of local tumour control (even if there is no firm evidence that such a complication influences survival).

To a large extent, ocular outcomes after treatment of uveal melanoma are determined by the success with which any side effects and complications are managed (e.g., macular oedema after radiotherapy, rhegmatogenous retinal detachment after endoresection). In this respect, the inclusion of an Onco-VR surgeon in the oncology team is valuable. [Secondary vitreoretinal procedures](#) include:

- Vitrectomy for vitreous haemorrhage

- Endodrainage of exudative retinal detachment
- Treatment of tractional and rhegmatogenous retinal detachment
- Tumour endoresection or exoresection for toxic tumour syndrome.



Local recurrence three years after trans-scleral resection performed in 1992. The patient required enucleation.

METASTATIC DISEASE FROM UVEAL MELANOMA

Before ocular treatment, it is conventional practice to screen all patients with uveal melanoma for systemic metastases, by performing a liver scan, chest x-ray, and liver function tests. Some oncologists reserve such screening for patients with a large tumour (i.e., basal tumour diameter >16 mm) and/or any suspicious symptoms (i.e., abdominal pain, weight loss, anorexia, etc.).

After ocular treatment for uveal melanoma, some centres offer systemic surveillance for metastatic disease to all. [Others offer such surveillance only to patients with a 10-year risk of metastatic death exceeding 10%, if the tumour is large or if genetic investigations show the uveal melanoma to have a lethal genetic aberration \(i.e., chromosome 3 loss, BAP1 loss, et.](#)

With regards to screening methods, to detect pre-symptomatic metastases, it is necessary to perform liver imaging with methods such as US or MRI. Such imaging tends to be performed every six months for 5-10 years, then once a year indefinitely; however, there is no consensus regarding the best protocol. We prefer these imaging methods to those that expose patients to ionizing radiation (e.g., CT); these tend to be reserved for staging once metastases are detected.

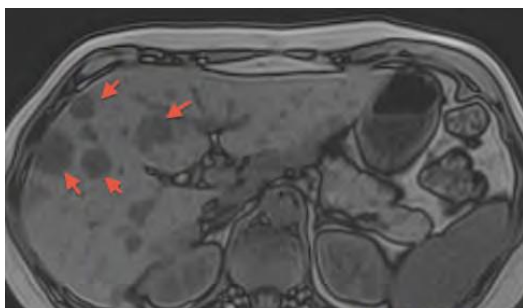
Biochemical liver function tests performed annually are of little value. Chest x-ray only rarely detects lung metastases in the absence of liver tumours.

Treatment

[Treatment of metastatic disease](#) has [improved in recent years](#), although the prognosis is still poor.

Metastases from uveal melanoma have a low rate so that they are less immunogenic and therefore less responsive to immune checkpoint inhibitors than cutaneous melanomas, except in patients with a [uveal melanoma showing MBD4 inactivation](#) and perhaps those with very early detection of hepatic metastases.

Encouraging results have been reported with [Tebentafusp](#) (Immunocore, Abingdon, UK), which links the patient's own T-cells with melanoma cells; however, this is effective only in patients who are positive for HLA-A*02:01. This is found in only 25% of the population (Patel, S. ISOO 2024).



MRI scan showing hepatic metastases from uveal melanoma

Chemosaturation therapy involves perfusion of the liver with melphalan, through the hepatic artery, with hepatic vein isolation and extraction of the drug with a CHEMOSAT® (Delcath, NY, USA) filter to reduce systemic toxicity.

Prolonged survival can occur after surgical resection of isolated hepatic metastases.

COUNSELLING

Counselling of patients with uveal melanoma is a very important aspect of care, not only at the first consultation but also subsequently. Important topics include:

- Basic ocular anatomy (with a real or virtual model of the eye)
- Diagnosis of possible or definite uveal melanoma.
- Possible outcomes without treatment.
- Objectives of treatment.
- Treatment options with risks and benefits of each.
- Prognosis in terms of metastatic disease and survival, ocular conservation, local tumour control, preservation of vision.
- Short- and long-term management plans.
- Sources of information
- Patient advocacy groups

It is helpful to give patients a [taped](#) or [digital](#) audio recording of the discussion to help them remember what was said.

[Large-language models](#) may give inaccurate information that is misleading for a particular individual.

The specialist ocular oncology nurse also plays an important role, for example: (a) speaking to each patient immediately after the initial consultation; (b) visiting all patients in the ward; (c) telephoning every patient a few days after discharge from hospital; (d) providing a telephone helpline; and, on request, (e) arranging for new patients to speak to similar patients who have previously had the same treatment.

A study in the US identifies [shortcomings in counselling](#) that tend to cause patient's dissatisfaction with the care they received and includes a 'bill of rights' defining the care they should expect to receive.

There is growing awareness of the psychological morbidity that patients and their relatives experience and these issues are increasingly being addressed more fully.

FOLLOW UP

Ocular

There is much variation amongst ocular oncologists regarding the approach to ophthalmic surveillance after treatment for uveal melanoma. In this guide, we summarise the Moorfields strategy.

After enucleation, the ocular oncologist:

- discharges the patient to the local ophthalmologist requesting an in-person at the patient's home hospital four weeks after the operation.
- Four weeks post-operatively, the ocular oncologist (a) holds a phone/video consultation to inform the patient of any prognostic laboratory results and to ensure that the patient has appointments at the local hospital and at an artificial eye clinic, (b) revises care accordingly (e.g., if the patient has not yet received any appointments), and (c) sends a letter with pathology and genetics reports to the referring ophthalmologist, GP and medical oncologist.
- Six weeks post-operatively, the patient attends the artificial eye clinic and has an in-person consultation with the ocular oncologist if these are not held at local hospital. The ocular oncologist discharges the patient to the local hospital suggesting one in-person consultation six months post-operatively followed by discharge to the local optometrist.
- **At the local hospital**, patients require:
 - Examination of the socket, once, with further assessments by the ocularist, who would refer the patient back to an ophthalmologists if any problems ever arise.
 - Liver imaging as directed by the ocular oncologist, if not undertaken by a medical oncologist.

After radiotherapy the ocular oncologist:

- Sends a letter to the referring ophthalmologist requesting an in-person consultation at the patient's local hospital four weeks post-operatively and, if necessary, suggesting adjunctive anti-VEGF injections vs 'toxic tumour syndrome'. The ocular oncologist also organises an in-person consultation at the ocular oncology centre six months after treatment.

- Six weeks post-operatively, the ocular oncologist conducts a video or phone consultation with the patient, informing the patient of any prognostic laboratory results, checking whether care has been established at the local hospital and, if not, organising an in-person consultation at the oncology centre.
- Six months post-operatively and then every six months the patient is reviewed at the ocular oncology centre until visible choroidal atrophy develops around the tumour, when the patient is discharged to the local hospital, unless relapse occurs.
- Patients local to Moorfields or who have a ciliary body tumour requiring ultrasound biomicroscopy may continue to have annual follow-up assessments at Moorfields until it is considered safe to discharge the patient to the local eye hospital.

At the local hospital, patients require sequential colour photography, fundus autofluorescence imaging, and/or optical coherence tomography, depending on tumour location, every six months for the first five post-operative years, and then once a year, indefinitely.

At Oxford Eye Hospital, these images are reviewed and reported on by an ophthalmologist with special expertise in ocular oncology (i.e., an 'ocular oncology specialist'). If possible, this is done remotely in a 'virtual clinic' within a few days of the patient's attendance at the photography unit for imaging. If necessary, the patient is seen 'face-to-face' by the specialist in a dedicated ocular oncology clinic if:

- the patient requires emotional support (e.g., if recently been diagnosed with uveal melanoma or local tumour recurrence),
- the tumour cannot be adequately imaged (e.g., if a choroidal tumour extends beyond the range of available fundus cameras or if an iris tumour involves the angle),
- an in-depth discussion is needed (e.g., whether or not to administer anti-VEGF treatment for radiation-induced macular oedema),
- the management is controversial (e.g., treatment for a small choroidal melanoma has been deferred until growth is detected),

- the patient prefers to be seen in person.

Ocular ultrasonography is not required unless an increase in tumour thickness is suspected, in which case the patient should be referred back to the ocular oncology centre. If ultrasonography is performed, the tumour thickness should be measured from the internal scleral surface, excluding retina.

If cataract develops, it should be treated to enable monitoring of the posterior segment.

If media opacities are untreatable (e.g., retinal detachment, phthisical eye, vitreous haemorrhage), the patient should be referred back to the ocular oncology centre.

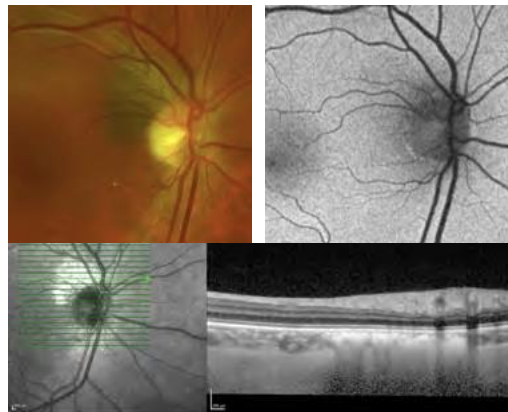
CHOROIDAL NAEVUS

[Choroidal naevi](#) are reported to occur in about 5 to 10 percent of the population, with about 90 percent developing posterior to the equator. The large majority of naevi are less than 2 mm in diameter. Malignant growth is rare.

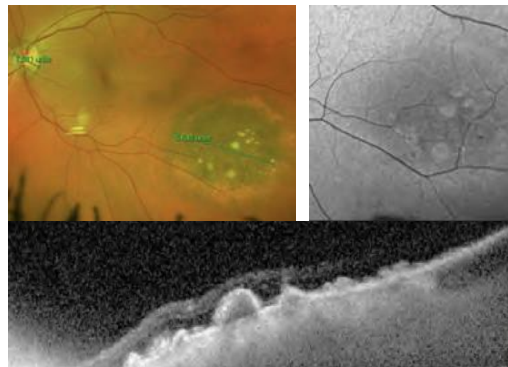
It can be difficult to differentiate choroidal naevi from melanomas. Damato has therefore developed the [MOLES acronym, scoring system](#) and management guidelines to avoid unnecessary referral of patients with choroidal naevi to hospital eye clinics while expediting diagnosis and treatment of patients with choroidal melanoma.

MOLES SCORING SYSTEM

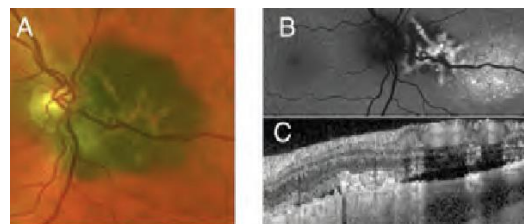
Clinical Feature	Score
<ul style="list-style-type: none"> Mushroom shape Nil = 0 Incipient, with erosion of RPE = 1 Present, with overhang = 2 	
<ul style="list-style-type: none"> Orange pigment Absent = 0 Minimal dusting = 1 Confluent clumps = 2 	
<ul style="list-style-type: none"> Large size Diameter <3DD and thickness <1.0mm = 0 Diameter 3-4DD and/or thickness 1-2mm = 1 Diameter >4mm and/or thickness >2mm = 2 	
<ul style="list-style-type: none"> Enlargement* Nil or new tumor but no previous exam = 0 Uncertain / 'new tumor but no old image' = 1 Definite, with sequential imaging = 2 	
<ul style="list-style-type: none"> Subretinal fluid Nil = 0 Minimal, visible only with OCT = 1 Significant, visible ophthalmoscopically = 2 	
* Assume growth and score enlargement >0 if diameter >5 DD or thickness >3 mm.	Total Score



Common choroidal naevus (MOLES score = 00000 = 0). The colour photograph shows the small tumour size. The autofluorescence image excludes lipofuscin. The OCT shows the tumour to be flat with no subretinal fluid. Contrary to previous reports, juxtapapillary location is not a sign of malignancy.



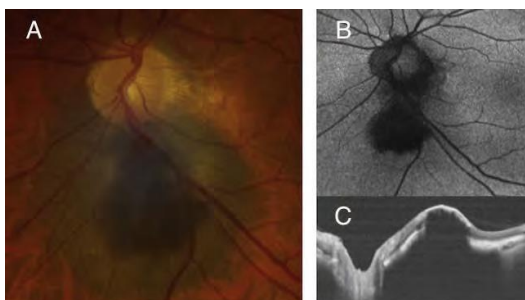
Low-risk choroidal naevus (MOLES = 00100 = 1) with a diameter of 3-4DD, a thickness < 1 mm, no orange pigment and no subretinal fluid. Drusen on the tumour surface indicate chronicity. The tumour has a partial halo, which is reported to be associated with a relatively low risk of malignancy.



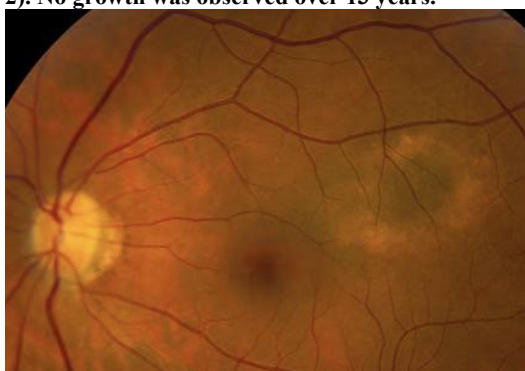Choroidal melanoma with clumps of confluent orange pigment, which on FAF is hyper-autofluorescent and which on OCT is seen on the retinal surface of the RPE (unlike drusen, which are located between RPE and Bruch's membrane). There is also subretinal fluid.

Mushroom shape is almost pathognomonic for choroidal melanoma. It occurs when the tumour extends through Bruch's membrane and retinal pigment epithelium (RPE). When this happens, the tumour thickness increases so that the MOLES score exceeds 2. A score of 1

indicates that the tumour bulges slightly through a defect in Bruch's membrane.

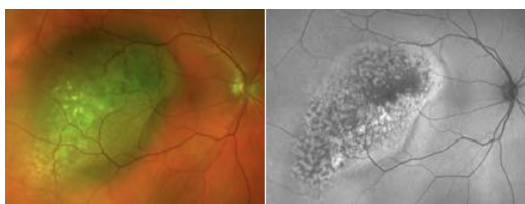


High-risk choroidal naevus with tumour spread into the retina as shown by the OCT and the hypoautofluorescence on FAF (MOLES score = 10100 = 2). No growth was observed over 13 years.



Choroidal naevus (MOLES = 00000). The lesion is unusual because it has a halo, which is said to be a reassuring feature.

Orange pigment, consisting of lipofuscin, accumulates on the retinal surface of the RPE overlying choroidal melanomas, particularly posterior to the equator. Light dusting of orange pigment can occur over choroidal naevi and is given a MOLES score of 1; however, clumps of confluent orange pigment tend to occur with melanomas, hence the score of 2. Over amelanotic tumours, lipofuscin can appear brown. This pigment is hyper-autofluorescent. On OCT, lipofuscin forms fluffy deposits on the retinal surface of the RPE, unlike drusen, which form discrete lumps between RPE and Bruch's membrane. Note that orange pigment can appear over other tumours, such as metastases and haemangiomas.



Amelanotic choroidal melanoma imaged with the Optos camera, showing golden-coloured lipofuscin, which is hyperfluorescent.

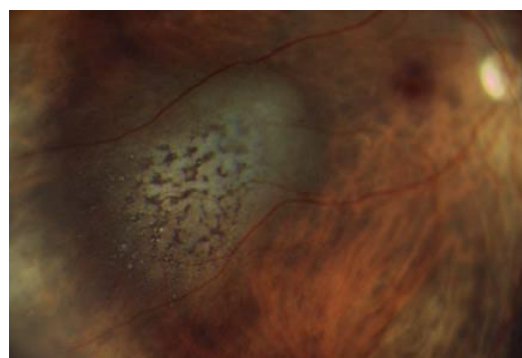


Fig. Amelanotic choroidal melanoma photographed with the Panoret camera, showing lipofuscin as dark-brown clumps

Larger size. Choroidal melanomas tend to be wider and thicker than naevi, although there is some overlap. Augsburger et al found that there are approximately 125 choroidal naevi for every melanoma in the thickness range of 1.5 to 2 mm, 25 naevi for every melanoma in the thickness range of 2 to 2.5 mm, and 5 naevi for every melanoma in the thickness range of 2.5 to 3 mm.

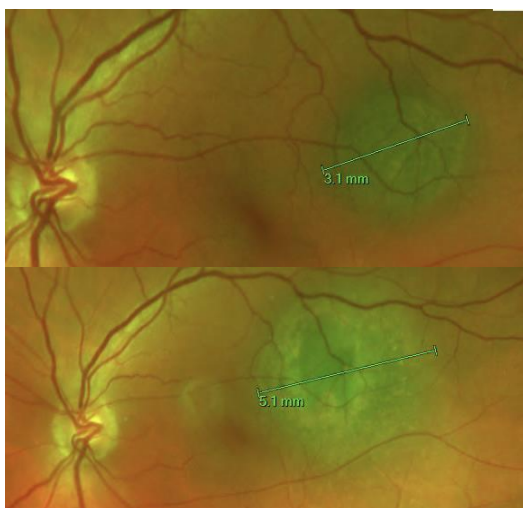
Erring on the side of caution, the tumour thickness is given MOLES scores of 0, 1 and 2 if the tumour thickness is <1 mm, 1-2 mm or >2 mm respectively (i.e., 'flat/minimally thickened', 'slightly dome shaped – seen with difficulty on ophthalmoscopy', and 'significantly elevated - easily visible on ophthalmoscopy'). If possible, the thickness of small, posterior lesions should be documented by performing optical coherence tomography (OCT). Ultrasonography may be useful when OCT is not possible because of large tumour size or peripheral location.

[Augsburger et al](#) found that there are approximately 70 naevi for every choroidal melanoma in the basal diameter range of 5 to 6 mm, 10 naevi for every melanoma in the diameter range of 6 to 7 mm, and 3 naevi for every melanoma in the range 7 to 8 mm. The MOLES system therefore scores basal diameter as 0, 1 or 2 if measurements are <3 DD, 3-4 DD, and >4 DD respectively (1DD=1.5 mm. Tumours rarely become thicker without also showing an increase in diameter; colour photography should therefore be sufficient when OCT and ultrasonography are not possible.

Enlargement of choroidal naevi is rare after the age of 25 years, and when it occurs it is minimal and slow (i.e., <0.5 mm/yr). Sequential fundus photography makes it easier to detect tumour growth, especially if distances between tumour

margins and nearby retinal landmarks are assessed.

Tumour enlargement confirmed photographically is given a MOLES score of 2. If photography suggests growth but is inconclusive, because of poor image quality, a score of 1 is given. A score of 0 is given if a lesion is detected and if the patient was not seen previously. A score of 1 is given if no lesion was documented or mentioned to the patient after previous ophthalmoscopy and if its absence previously not confirmed photographically.



Growth of a choroidal melanoma, best seen using retinal blood vessels as a guide (more sensitive than assessing basal diameter)

In our opinion, when monitoring suspicious lesions, [ultrasonography is not required if sequential colour photography does not suggest growth](#). This is because it is rare for tumours to grow thicker without becoming wider and/or showing other signs of progression, such as RPE perforation or increasing amounts of orange pigment and/or subretinal fluid.

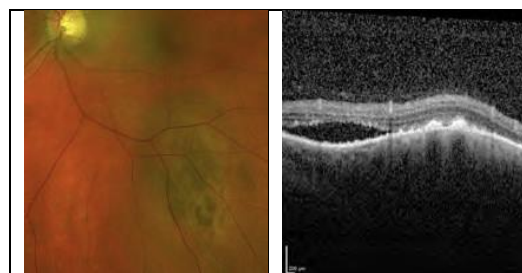
Large tumours (i.e., >5DD wide or >3 mm thick) are assumed to have grown and are given an Enlargement score of 1. This is because lipofuscin and subretinal fluid may not be visible in colour images of large, anterior melanomas.

MOLES was originally intended for optometrists but is being used by ophthalmologists and even ocular oncologists. For tumours monitored by such experts, Damato suggests an E score of 0 if no growth is documented, 1 if the basal tumour

diameter in the tumour meridian showing most growth increases by up to 5%% per year, and 2 if growth rate exceeds this value.

Subretinal fluid (SRF) develops when RPE function is disturbed by an underlying choroidal tumour. The retina is flat over typical naevi (i.e., MOLES score = 0) but some larger lesions may show minimal or localised detachment, which is given a score of 1. Significant and extensive retinal detachment that extends beyond the tumour margins ophthalmoscopically is given a MOLES score of 2.

Subretinal fluid is best detected with OCT. Cystoid spaces within the retina itself indicate chronicity and are given a score of 0. RPE and retinal changes caused by fluid gravitating from the tumour are also given a score of 0 if there is no longer any retinal detachment.



Retinal detachment, best demonstrated with OCT

Some choroidal naevi are atypical because of large size, de-pigmented halo, drusen, a choroidal neovascular membrane, or amelanotic appearance.

The mnemonic [TFSOM](#) (To find small ocular melanoma) previously stood for: Thickness, Fluid, Symptoms, Orange pigment, and Margin near disc. Proximity to disc is no longer considered to indicate malignancy. 'M' now represents 'melanoma hollow on ultrasonography'. The letters '-DIM' (doing imaging) have been added to represent 'Diameter more than 5mm'. Unlike TFSOM, MOLES does not require ultrasonography. This is because many clinics lack the skill and equipment needed to assess internal acoustic reflectivity of thin tumours.

Tentative recommendations for patient management:

- MOLES = 0: Self-care, advising patient to attend optometrist every 2 years.
- MOLES = 1: Non-urgent referral to hospital eye clinic for assessment, then follow up

after 6 months by an ophthalmologist, then once a year, by an optometrist or ophthalmologist.

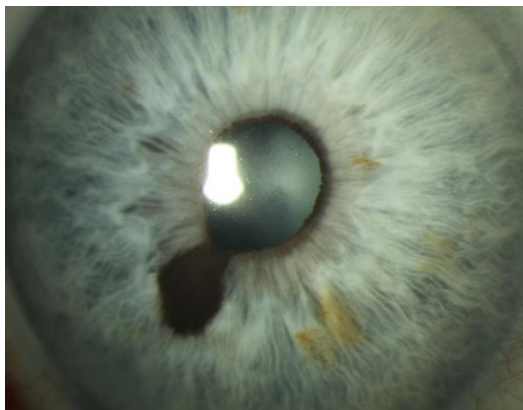
- MOLES = 2: Non-urgent referral to hospital eye clinic for assessment, then follow up every 6 months for 2 years, then once a year by an ophthalmologist.
- MOLES >2: Urgent referral to ocular oncologist.

[Implementation of MOLES at a virtual choroidal naevus clinic](#) in Bristol was found to be easy to implement and resulted in 162/283 (57.2%) patients being discharged to their optometrist.

At Oxford Eye Hospital, choroidal naevi are reviewed by an ocular oncology specialist, either at a virtual clinic or at a dedicated oncology clinic if imaging of the lesion does not allow remote assessment.

When patients are discharged, they are given a photograph of their naevus to take to their community optometrist every 1-2 years.

IRIS NAEVUS



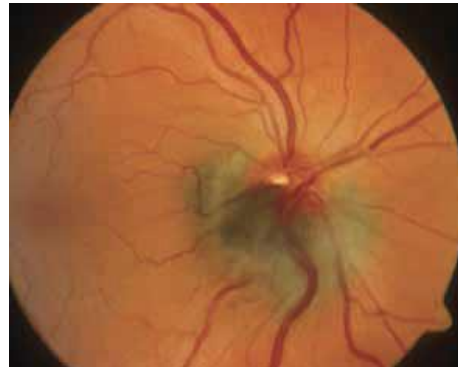[Iris naevi](#) are usually less than 3 mm in diameter and tend to occur inferiorly. They can cause ectropion uveae or a pupil margin cyst. As with other naevi, they can grow in the first two decades of life.

Management

Because of the risk of malignant growth, patients require life-long surveillance, by their community optometrist if the lesion is small or by an ophthalmologist if the lesion is large and/or involves the angle so that gonioscopy and perhaps UBM are required.

MELANOCYTOMA

[Melanocytoma](#) is usually seen at the optic disc but can arise anywhere in the uveal tract.



Melanocytoma, with no change after several years
This tumour can show malignant growth, either because of malignant transformation (reportedly in 1-2% of cases) or if a melanoma has mistakenly been diagnosed as melanocytoma.

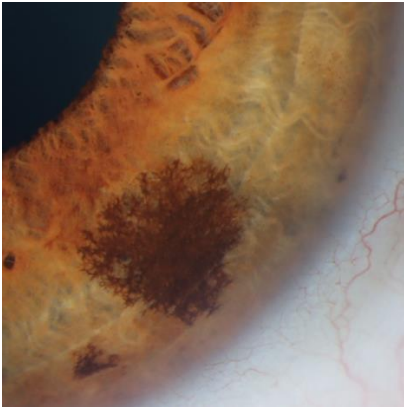
Melanocytomas can grow slowly, may extend extraocularly and can also undergo necrosis to cause pigment dispersion, as well as: (a) optic nerve compression and acute visual loss if the tumour is located at the optic disc.

[Iris melanocytomas](#) are deeply pigmented, with a granular surface. They can cause pigment dispersion and secondary glaucoma, especially if necrosis occurs.

Management

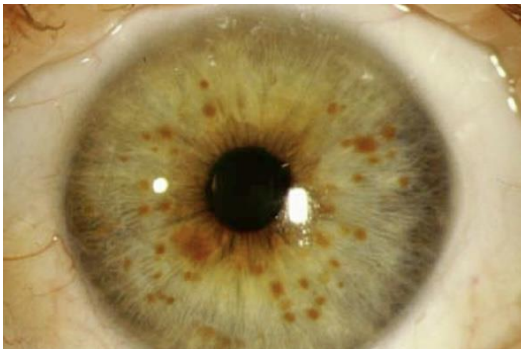
Patients with melanocytoma tumour are managed in the same way as those with a suspicious naevus, with review by an ophthalmologist at the local eye hospital after six months then once a year, indefinitely. Referral to an ocular oncologist is indicated if the diagnosis is uncertain or if tumour growth is seen.

IRIS FRECKLE



Iris freckles consist of melanocytes, which form a 'canopy' on the iris surface, without disturbing the iris anatomy. These freckles have no systemic associations and no malignant potential. Patients with iris freckles can therefore be reassured and discharged.

LISCH NODULES



[Lisch nodules](#) are small melanocytic proliferations on the iris surface. They are found in about 50% of patients with neurofibromatosis type 1 by the age of 5 years and in all patients with this condition by adulthood.

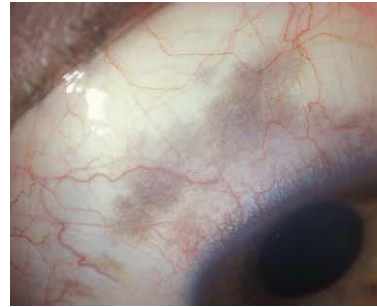CONGENITAL OCULAR MELANOCYTOSIS

[Congenital ocular melanocytosis](#) (COM) (also known as congenital ocular melanosis and oculo-dermal melanocytosis (i.e., naevus of Ota)) are associated with a [1 in 400 risk of uveal melanoma](#), which tends to be relatively aggressive with an [increased risk of metastasis](#). About 10% of affected eyes develop glaucoma. There is an association between melanocytosis and bilateral Sturge-Weber syndrome.

Diagnosis

Diagnosis is based on any of the following:

- Iris heterochromia, sometimes with multiple 'nipple-like' lesions known as mammillations.
- Slate-grey episcleral pigmentation.
- Skin pigmentation around eye.
- Choroidal pigmentation.



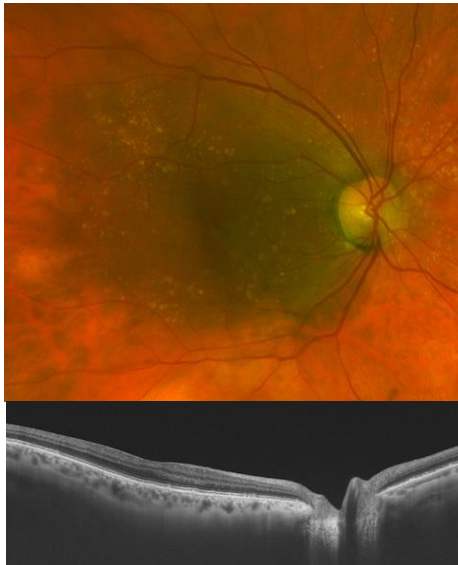
Congenital ocular melanocytosis (naevus of Ota). Note the slate grey scleral pigmentation. The overlying conjunctiva is clear and transparent. The melanocytosis also involves a sector of the iris

COM is sub-conjunctival and should be distinguished from conjunctival melanosis by dragging the conjunctiva from side to side with a cotton bud after administering an anaesthetic drop and noting whether the pigmented tissue moves.

Multiple ocular melanomas (and orbital melanoma) can occur in this condition. COM can cause glaucoma, which needs to be excluded at every visit.

Management

Extensive COM is managed in the same way as high-risk naevus (i.e., MOLES score = 2), with annual binocular indirect examination with mydriasis by an ophthalmologist. Ciliary body melanoma is detected by noting dilated episcleral vessels if UBM is not possible. Although the risk of melanoma is less in non-Whites, all patients with this condition should undergo life-long surveillance.



Isolated congenital choroidal melanocytosis, with pigmentation on fundus photography and no solid tumour on OCT.

Some patients show [isolated congenital ocular melanocytosis](#); the chances of melanoma in such cases are likely to be remote.

Management

These patients should be given a photograph of the lesion and advised to attend their community optometrist once a year, indefinitely.

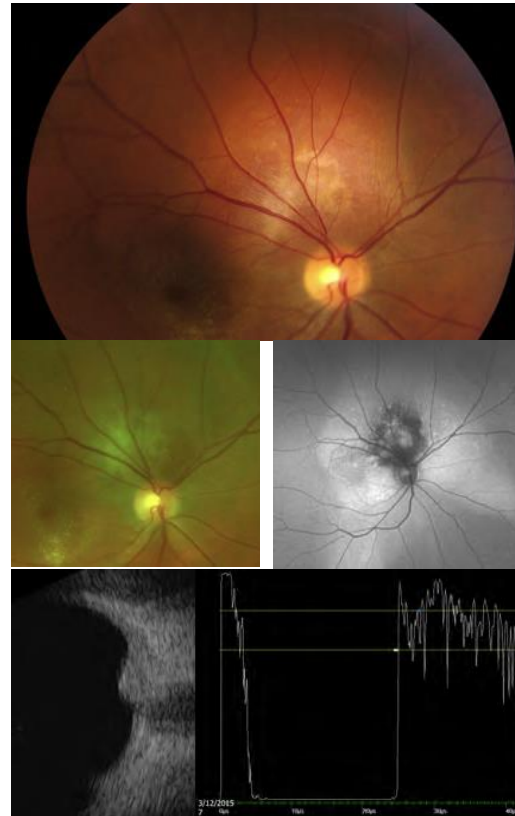CHOROIDAL HAEMANGIOMA

[Choroidal haemangiomas](#) usually develop posteriorly, near the optic disc or fovea. They can be nodular ('circumscribed') or diffuse.

A choroidal haemangioma can remain asymptomatic or can cause exudative retinal detachment, with visual loss and, eventually, painful neovascular glaucoma.

Diagnosis

US shows high acoustic reflectivity. Fluorescein angiography is not helpful. Although indocyanine green angiography can show 'late washout', this investigation is rarely necessary.



Circumscribed choroidal haemangioma imaged with standard colour photography, Optos, autofluorescence imaging, B-scan ultrasonography and A-scan ultrasonography. The tumour has the same colour as the surrounding choroid and shows a high internal acoustic reflectivity.

Management

CIRCUMSCRIBED HAEMANGIOMA

If a circumscribed haemangioma is asymptomatic, treatment is not necessary so that the patient can be discharged to their community optometrist, to whom they should present without delay if symptoms ever develop.

Symptomatic tumours should be treated semi-urgently because the chances of therapy improving vision diminish if visual loss is severe and/or prolonged. Vision may remain poor if the eye is amblyopic.

The first choice of therapy is [photodynamic therapy](#). Possible [side effects](#) include macular atrophy, cystic degeneration of the retina, and RPE metaplasia. It may be necessary to repeat the photodynamic therapy if retinal detachment persists after more than two months. If this is not possible, then monthly [intravitreal anti-angiogenic injections](#) may improve vision. [Delayed recurrence](#) of subretinal fluid has been reported in up to 35% of cases. Some authors therefore advocate

[double-fluence](#) or double-dose PDT.

Radiotherapy can also be effective but is avoided if possible. When irradiation is necessary, proton beam radiotherapy reduces exposure of healthy tissues to radiation.

DIFFUSE CHOROIDAL HAEMANGIOMA

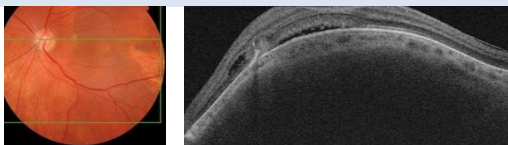
Diffuse choroidal haemangiomas are usually extensive and often associated with a bullous retinal detachment. They can be associated with:

- [Sturge-Weber syndrome](#), which includes facial naevus flammeus, glaucoma and [meningeal calcification](#).
- [Phacomatosis pigmentovascularis](#), which includes naevus flammeus, naevus of Ota and, therefore, [uveal melanoma](#), in rare cases.
- [Klippel-Trenaunay syndrome](#), which includes naevus flammeus, soft tissue and bone hypertrophy, and other features.

Photodynamic therapy may fail if the choroidal haemangioma is extensive. Alternative methods of treatment include [plaque radiotherapy](#), [external beam radiotherapy](#), [proton beam radiotherapy](#), [topical](#) or [oral beta blockers](#), and [oral sirolimus](#).

These patients require lifelong monitoring by an ophthalmologist, if possible at their local hospital, to detect and treat glaucoma and any other morbidity that can arise.

DOME-SHAPED MACULA



[Dome-shaped macula](#) is associated with myopia and posterior staphyloma. It can cause serous retinal detachment involving fovea, retinoschisis, choroidal neovascularisation, macular hole, epiretinal membrane. Optical coherence tomography shows the dome-shaped sclera, with a normal choroid and, in many cases, secondary effects in the retina.

It is not a tumour but is mentioned here because it can be mistaken for haemangioma.

Management

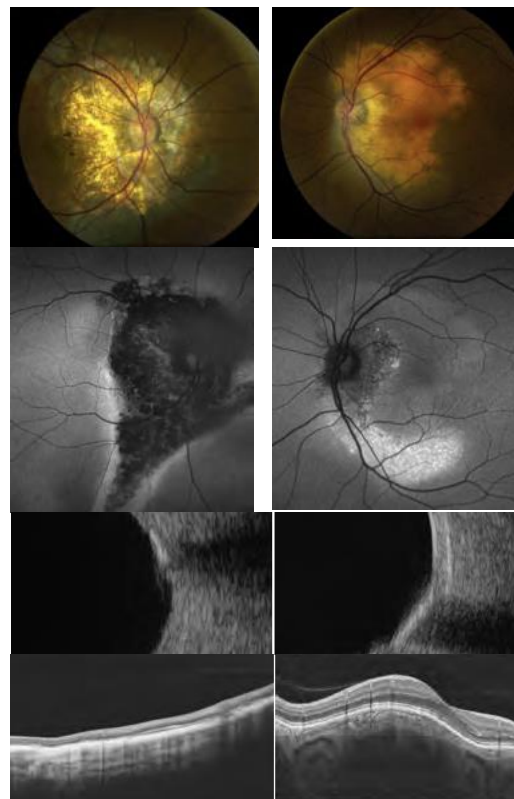
Patients with this condition can be discharged with the advice to seek medical attention if they ever notice deterioration of vision.

CHOROIDAL OSTEOMA

[Choroidal osteoma](#) can affect the fovea both directly and by inducing choroidal neovascularization. Spontaneous decalcification of choroidal osteoma causes RPE atrophy and visual loss if the fovea is involved.

Diagnosis

Ultrasonography shows the very high acoustic reflectivity of the tumour surface, with orbital shadowing. Areas of RPE atrophy are non-autofluorescent on FAF. OCT shows transverse layering within the tumour.



Bilateral choroidal osteomas, progressing in the left eye and regressed in the right eye. Colour photography shows these lesions to be pink in the left eye and yellow in the right eye. FAF shows normal autofluorescence where RPE is present in the left eye and hypo autofluorescence where RPE is atrophic in the right eye. Ultrasonography shows highly reflective lesions, with orbital shadowing. OCT shows the layering within the tumour in the left eye and flattening of the tumour in the right eye.

Management

If the fovea is not involved, the patient should be monitored by an ophthalmologist in case the tumour threatens central vision, in which case [photodynamic therapy](#) may induce tumour regression and and arrest further growth.

Any choroidal neovascularisation causing visual loss is treated with intravitreal anti-angiogenic therapy.

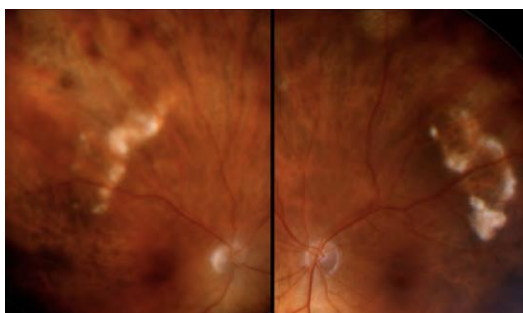
SCLERO-CHOROIDAL CALCIFICATION

[Sclero-choroidal calcification](#) is a degenerative condition causing linear intra-scleral calcification, usually in the region of the oblique muscle insertions.

Ultrasonography shows high reflectivity with orbital shadowing. No treatment is needed unless a choroidal neovascular membrane develops. This condition is usually idiopathic but may be associated with disordered calcium metabolism in patients with conditions such as Bartter's syndrome, Gitelman syndrome, hyperparathyroidism, and hypervitaminosis D.

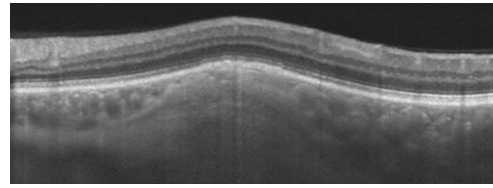
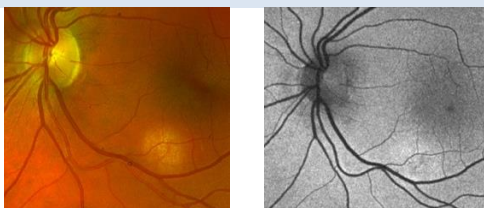Management

[Investigation of calcium metabolism](#) is indicated. Patients can be discharged with the advice on what to do if they ever notice blurred or distorted vision, if choroidal new vessels ever develop.



Bilateral sclero-choroidal calcification

IDIOPATHIC OCULAR SCLEROMA



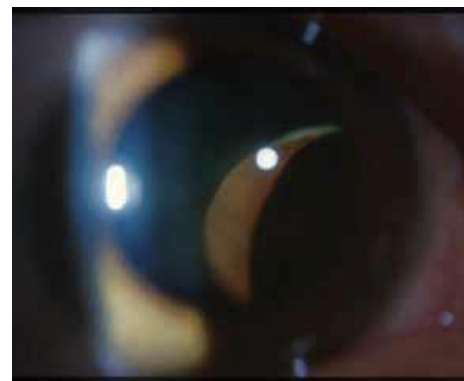This scleral nodule, which Damato et al have termed '[idiopathic ocular scleroma](#)', compresses the overlying choroid, causing RPE atrophy. US shows no orbital shadowing. Another term is '[focal scleral nodule](#)'. It was previously called 'solitary idiopathic choroiditis', but is neither choroidal nor inflammatory

Management

Idiopathic scleroma is harmless so that patients can be reassured and discharged.

NEUROFIBROMA, NEURILEMMOMA AND LEIOMYOMA

[Neurilemmomas](#), neurofibromas and [leiomyomas](#) usually develop in the ciliary body but can occur anywhere in the choroid. Although clinical features allow a tentative diagnosis, histology is required for confirmation. Most are diagnosed after local resection, biopsy or enucleation. Treatment is by trans-scleral local resection, which is a specialised procedure.



Ciliary body neurilemmoma mimicking melanoma. The tumour is amelanotic but appears pigmented because of the overlying pigment epithelium.

ASTROCYTIC HAMARTOMA

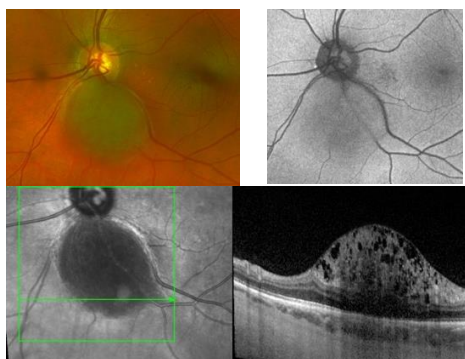
[Multiple astrocytic retinal hamartomas](#) usually occur in children in association with tuberous sclerosis, but a solitary lesion can arise at any age in otherwise healthy individuals. Systemic disease is excluded by: (a) dermatological

examination; (b) MRI brain scan for intra-cranial lesions; (c) family studies; and (d) molecular genetic studies. These are organised in collaboration with a geneticist. Most astrocytic hamartomas are static and asymptomatic.

Management

Any vitreous haemorrhage, neovascular glaucoma and optic nerve damage may be treated with [photodynamic therapy](#), [anti-VEGF therapy](#), an [mTOR inhibitor](#) (e.g., sirolimus), or, if vitreous haemorrhage is present, vitrectomy.

Patients a solitary lesion can be discharged with advice on what to do in the rare event of any related symptoms. Those with multiple lesions should be referred to a neurologist or geneticist if not known to have tuberous sclerosis.

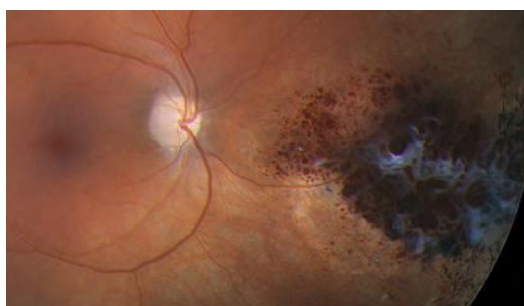

Astrocytic hamartoma

RETINAL CAVERNOUS ANGIOMA

[Retinal cavernous angioma](#) is rare. The diagnosis is based on:

- Ophthalmoscopic appearances
- A positive family history.
- Epilepsy and other disease caused by CNS lesions.
- Capillary angiomas on neck or trunk.



Cavernous retinal angioma, resembling a bunch of grapes

Management

The patient and any close relatives require neurological examination with MRI scans because of a 14% risk of [intracranial angiomas](#), which can cause severe brain haemorrhage.

Photocoagulation of retinal lesions is avoided because it can result in haemorrhage and tumour enlargement.

RACEMOSE ANGIOMA

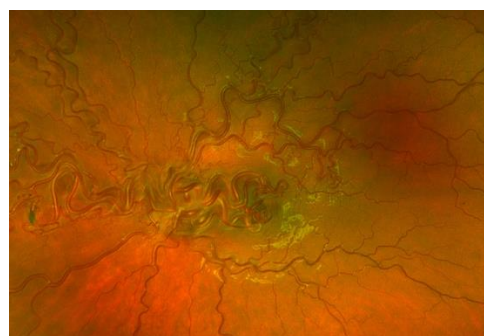
[Retinal racemose angioma](#) (also known as retinal arteriovenous malformation) is grouped as:

1. Abnormal capillary plexus between major retinal blood vessels.
2. Direct AV communication without interposed capillaries
3. Extensive AV communications, possibly associated with CNS and cutaneous lesions ([Wyburn-Mason syndrome](#))

Management

No ocular treatment is required unless there are complications, which are treated as appropriate.

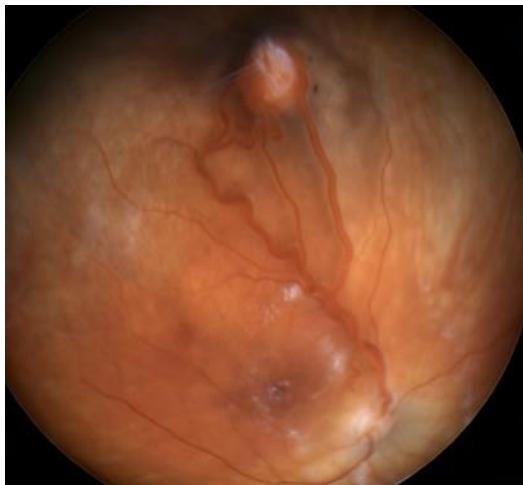Patients require brain MRI to detect or exclude CNS disease and are advised about the risk of haemorrhage after dental extraction, which can occur if there are any vascular malformations in the jaw.



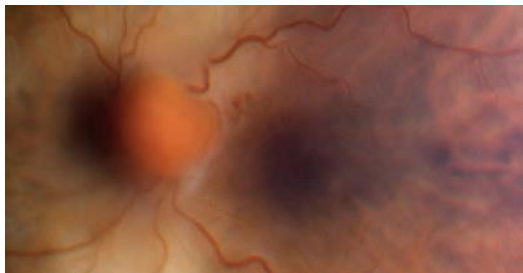
Racemose angioma (Wyburn-Mason Syndrome)

RETINAL HAEMANGIOBLASTOMA

[Retinal haemangioblastoma](#) (retinal capillary angioma) can develop in isolation or in association with [von Hippel Lindau disease](#). Patients with this ocular tumour are therefore referred to a clinical geneticist and other specialists for systemic investigation and treatment.



Retinal hemangioblastoma, with feeder vessels



Capillary hemangioblastoma of the optic disc

Management

Patients with VHL syndrome require ophthalmoscopy every 6-12 months from the age of 1 year.

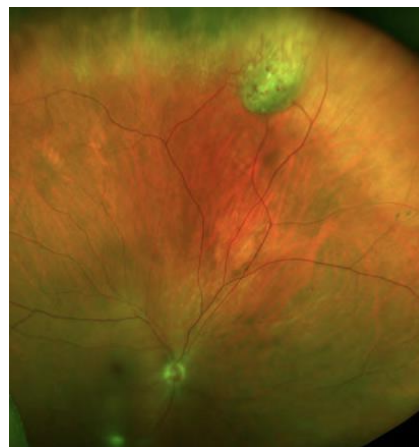
[Treatment of retinal lesions](#) can include: (a) photocoagulation or cryotherapy if small, depending on whether they are posterior or anterior, respectively; (b) photodynamic therapy; (c) ruthenium plaque radiotherapy if more than 1-2 DD in size; or (d) vitreoretinal surgery if vitreous bands and tractional retinal detachment are present.

Suggested treatments for juxtapapillary lesions include anti-angiogenic therapy (e.g., Avastin, photodynamic therapy, and proton beam radiotherapy. Unfortunately, the prognosis is poor.

Encouraging early results have been reported with [belzutifan](#), a systemic HIF-2 alpha inhibitor, as well as with intravitreal sirolimus in combination with bevacizumab or aflibercept (Aykut A, ISOO 2024).

VASOPROLIFERATIVE TUMOUR

[Vasoproliferative tumour](#) (also known as retinal focal nodular gliosis) is a pink/yellow tumour usually located inferiorly, temporally and anteriorly. This condition may arise in isolation or in association with other ocular conditions, such as uveitis, previous retinal detachment, ocular trauma and retinitis pigmentosa. Visual loss can be caused by macular exudates and epiretinal membranes. Advanced tumours can cause total retinal detachment and neovascular glaucoma.



Vasoproliferative tumour

Management

Patients with small, inactive lesions can be reviewed [without treatment](#) by an ophthalmologist every 6-12 months.

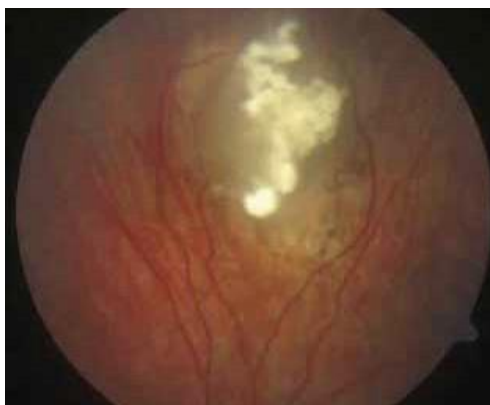If exudates threaten central vision, the tumour can be ablated by (a) [cryotherapy](#), (b) [photodynamic therapy](#), possibly in combination with anti-angiogenic therapy, or (c) [plaque radiotherapy](#). Advanced cases may require [vitreoretinal surgery](#).

At some stage, epiretinal-membrane peel may be necessary to improve vision.

RETINOBLASTOMA

[This disease only rarely affects adults](#). It can do so in the following ways: (a) development of a secondary malignant neoplasm of the orbital region or ocular adnexa after previous radiotherapy; (b) an inactive tumour, consisting either of a benign variant of retinoblastoma or a spontaneously regressed tumour, with both of these varieties threatening tumour recurrence; (c) development of adult

retinoblastoma, which is usually peripheral and often associated with clinical features resembling uveitis; and (d) development of retinal vasculopathy or cataract after previous radiotherapy for retinoblastoma.



Spontaneously regressed retinoblastoma in a teenager. This was later treated with a ruthenium plaque.

MEDULLOEPITHELIOMA

[Medulloepithelioma](#) is derived from retina and ciliary epithelium and usually presents in childhood. Very rarely, it can become manifest in adulthood. It can develop in about 1% of patients with the [DICER1 syndrome](#), almost always before the age of 10 years.

The diagnosis is based on slit-lamp examination and UBM. Secondary effects, such as glaucoma, cataract and retinal detachment, need to be excluded.

Management

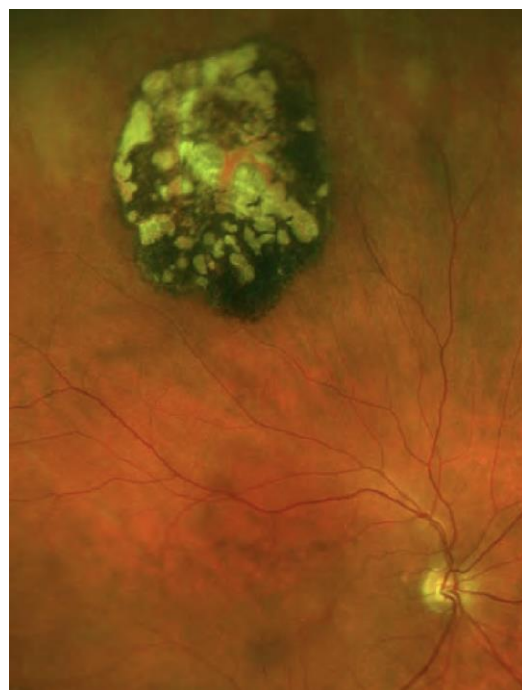
Small tumours may respond to plaque radiotherapy, but diffuse, large or recurrent tumours are treated by enucleation, with exenteration if there is orbital extension, because of the risk of intracranial spread, which can be fatal.

Patients with the Dicer1 syndrome require examination by an ophthalmologist until the age of 10 years, then annual review by their community optometrist.

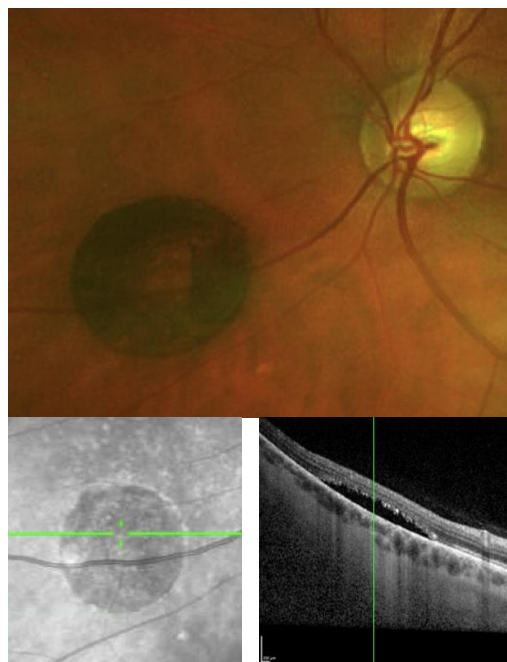CONGENITAL HYPERTROPHY OF THE RPE (CHRPE)

[CHRPE lesions](#) are flat and deeply pigmented, commonly with areas of RPE atrophy ('lacunae'), discrete margins, and, in some cases, a narrow de-pigmented 'halo',

photoreceptor loss and, rarely, a subretinal cleft.



Congenital hypertrophy of the retinal pigment epithelium, with discrete margins and lacune



CHRPE with retinal atrophy and a subretinal cleft

Solitary and clustered lesions (i.e., 'bear tracks' or 'cat's paws') do not have any systemic associations. They can be associated with white

or transparent, [benign lobular inner nuclear layer proliferations \(BLIPs\)](#) in the retina.

The presence of more than three spindle-shaped lesions affecting one or both eyes is associated with [familial adenomatous polyposis \(FAP\)](#), which predisposes to colon carcinoma. Most patients with FAP have CHRPE lesions. Patients with these lesions should be referred to a gastroenterologist unless FAP is already known to be present, in which case they can be discharged as they are unlikely to cause any ocular disease.

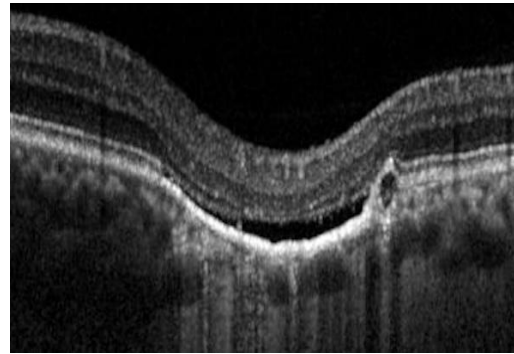
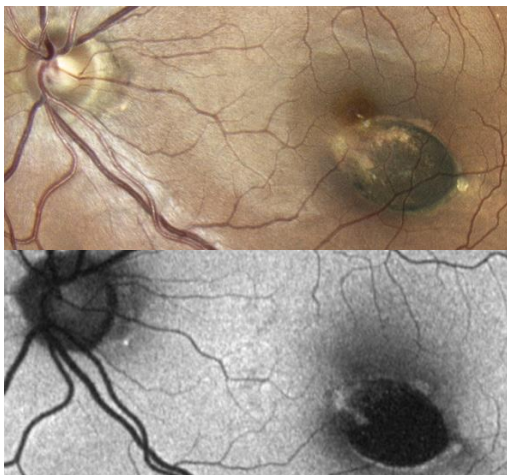
[Nodular tumours arising from CHRPE](#) have rarely been described and these are believed to be adenomas or low-grade adenocarcinomas.

Management

Review every two years by a community optometrist is indicated, because of the remote risk of nodule formation.

TORPEDO MACULOPATHY

[Torpedo maculopathy](#) is a congenital malformation usually located temporal to the fovea. It is a concave, oval, lesion with discrete margins, in some cases with outer retinal cavitation, choroidal thinning, and hyperpigmentation. It can give rise to a choroidal neovascular membrane with visual loss. There is no malignant potential.

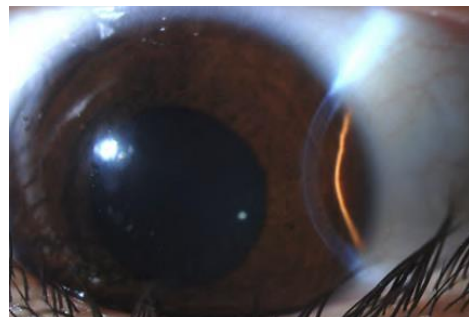


Management

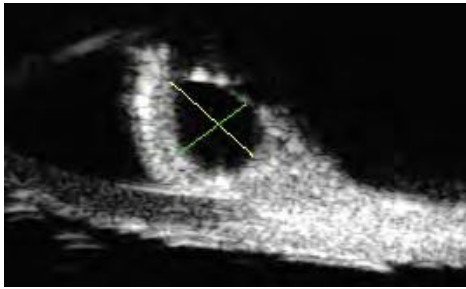
Patients can be discharged with the advice to seek urgent medical attention if they ever notice blurred or distorted vision with the affected eye, which may indicate choroidal neovascularisation needing treatment.

IRIS CYSTS

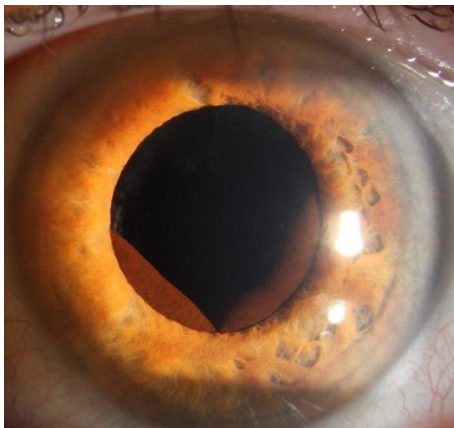- [Iridociliary cysts](#), pushing the iris forwards, possibly causing glaucoma and cataract. These are usually multiple and bilateral.
- Mid-zonal, protruding behind the pupil margin.
- Marginal, possibly associated with iris tumours such as naevus and melanoma.
- Stromal, developmental or occurring because of implantation of conjunctiva into the anterior chamber.
- [Dominant familial iris flocculi](#) are collapsed, pigmented iris cysts at the pupil margin, which may be inherited in an autosomal-dominant fashion, affecting both eyes and associated with dissecting aortic aneurysm, which may be fatal.



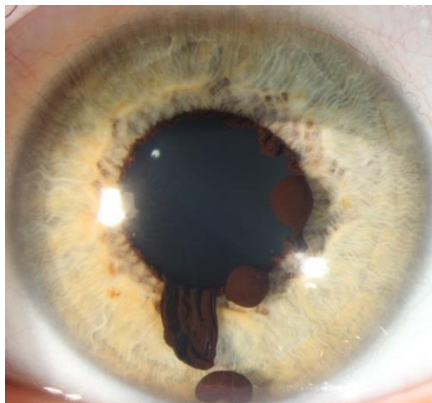
Iridociliary cyst, located temporally in the left eye, pushing the iris forward and narrowing the angle



Iridociliary cyst, confirmed with B-scan ultrasonography, which shows a hollow tumour. Multiple tiny cysts are usually also present, bilaterally



Mid-zonal iris cysts. Note the smooth surface.



Iris flocculi, which may be inherited in an autosomal dominant fashion and associated with fatal dissecting aortic aneurysm

Investigation

Examination includes slit-lamp examination and photography before and after mydriasis, gonioscopy, and, in selected cases, optical coherence tomography, and ultrasound biomicroscopy.

Management

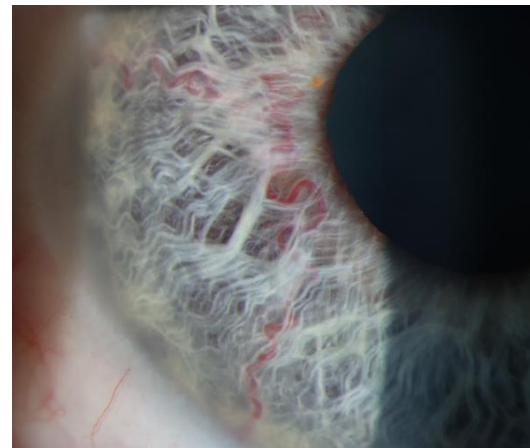
Asymptomatic iridociliary cysts can be monitored by a community optometrist for the development of glaucoma and cataract.

Symptomatic iridociliary cysts can be ruptured with argon or Nd-YAG laser treatment.

Patients with iris flocculi must be referred to a vascular surgeon, who will organise genetic tests to determine the risk of dissecting aortic aneurysm.

Stromal iris cysts threatening vision can be destroyed by collapsing the cyst by needle aspiration and performing cryotherapy or injecting alcohol, which is removed after a few minutes. This treatment may need to be repeated. Local resection is another option.

IRIS ARTERIOVENOUS MALFORMATION



Iris arteriovenous malformation consists of tortuous blood vessels in the iris stroma, which are innocuous with no systemic associations.

Management

Patients with iris arteriovenous malformation can be discharged with no need for monitoring.

ADENOMA AND ADENOCARCINOMA

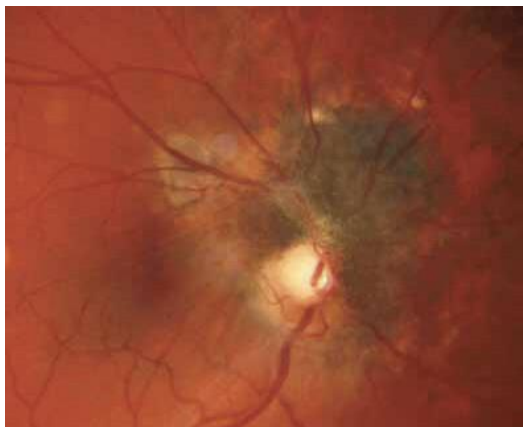
Adenoma and adenocarcinoma arise from retinal pigment epithelium, ciliary epithelium, CHRPE, or from chorioretinal scars. They can be pigmented or amelanotic and difficult to differentiate clinically from melanoma. These tumours tend to be diagnosed histologically, after resection.

Management

Although observation has been recommended, most ciliary body tumours are treated by

iridocyclectomy, which is useful both for diagnosis and treatment.

COMBINED HAMARTOMA OF THE RPE AND RETINA



Combined hamartoma of the RPE and retina

[Combined hamartoma of the RPE and retina](#) can affect the juxtapapillary retina or can be peripheral. The diagnosis is based on ophthalmoscopy and OCT. This lesion can cause retinal traction, retinoschisis, retinal detachment, vitreous haemorrhage, choroidal neovascularisation. Occasionally, epiretinal membrane surgery can improve vision. Occlusive therapy of the fellow eye has been recommended for children with visual loss. An association with neurofibromatosis has been reported.

Management

Patients should be examined for other features of neurofibromatosis (e.g., Lisch nodules). If the diagnosis is uncertain, they should be referred to an ocular oncologist; otherwise, they should be reviewed at their local eye hospital once a year having been advised what to do if symptoms ever develop.

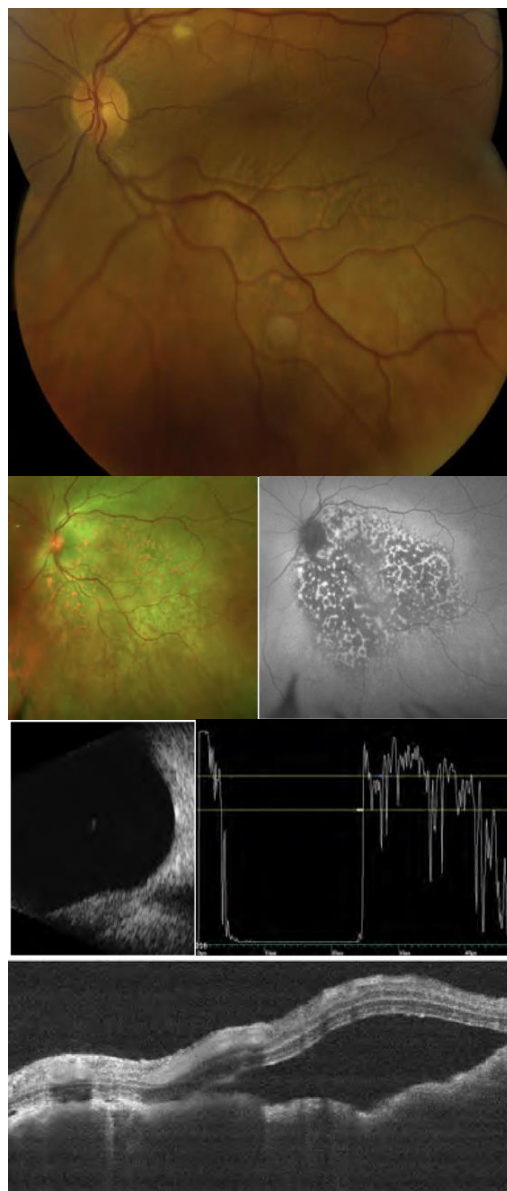
INTRAOCULAR METASTASIS

[Intraocular metastases](#) are common but often overshadowed by the systemic disease. Most uveal metastases arise in breast and lung. Metastases can be multiple and bilateral. They tend to grow relatively fast and cause extensive exudative retinal detachment.

Diagnosis

Metastases are usually posterior, amelanotic, and plateau-shaped, with indistinct margins, and exudative retinal detachment. Tumour

vasculature is not usually visible. There can be clumps of lipofuscin, which can appear brown. These tumours show medium reflectivity on ultrasonography, as well as hyper- and hypo-autofluorescent stippling on autofluorescence imaging. OCT shows a lumpy anterior surface, which is typical of this condition.



Choroidal metastasis with standard colour photography and Optos. FAF shows extensive clumps of orange pigment. US shows moderate internal acoustic reflectivity. OCT shows a typical lumpy surface with retinal detachment.

[Iris metastases](#) are rare. These grow rapidly, seeding into other parts of the anterior chamber, possibly causing pseudohypopyon, hyphaema, secondary glaucoma, loss of vision and pain.

Biopsy is useful for establishing the diagnosis and indicating the likely site of the primary cancer if this is not known. Some perform biopsy only as a last resort, when systemic investigations are inconclusive. Such testing can delay treatment, allowing the tumour to grow significantly and to cause irreversible visual loss. Also, systemic investigations may fail to detect the primary tumour. For these reasons, some therefore advocate biopsy in the first instance.

Management

Patients with ocular metastases require multidisciplinary care, with involvement of medical oncologists, radiotherapists, and other specialists.

If the patient is starting systemic therapy, ocular assessment is repeated about 4 weeks after completing the first course of therapy in the hope that the tumour regresses. Most patients receive external beam radiotherapy, which is delivered either over several weeks if the life-expectancy is good or over a few days if the prognosis for survival is poor. If the patient lives far from the ocular oncology centre, this external beam radiotherapy may be delivered at a hospital near the patient's home. Before starting ocular radiotherapy, it is important to exclude intracranial metastases, which would be treated at the same time. If the tumour is small, the ocular oncologist may attempt photodynamic therapy in the hope of sparing the patient from the inconvenience of external beam radiotherapy.

As a rule, all follow-up is at the local hospital, especially if the patient is unwell.

VITREORETINAL LYMPHOMA

[Vitreoretinal lymphoma](#) is strongly associated with [CNS lymphoma](#), which has a [high mortality](#). Patients are elderly, unless immunodeficient.

The lymphoma is believed to originate systemically, homing to brain, retina, and testis. Some believe that the tumour cells reach the retina via the retinal arterioles, then spread into the vitreous and infiltrate into the sub-RPE space, where they are trapped by Bruch's membrane so that they accumulate to form small deposits or large tumour masses.

Clinical features

These can include the following:

- Vitreous infiltrates, which can obscure the fundus.
- Anterior chamber cells, in some patients.
- Subretinal yellow-white tumour deposits, which can cause RPE atrophy when they regress.
- Retinal arteriolar sheathing and occlusion.
- Cystoid macular oedema (albeit rarely).
- Epiretinal membranes.
- Optic nerve infiltration with swelling and atrophy.

Investigations

Diagnosis requires [multimodal imaging](#).

- Ophthalmoscopy and wide-angle colour photography, to document subretinal deposits, vascular sheathing, and occlusion.
- Fundus autofluorescence imaging to show hyper-autofluorescent sub-RPE deposits and hypo-autofluorescent areas of RPE atrophy.
- OCT, which demonstrates sub-RPE deposits, cystoid oedema and epiretinal membranes.
- Vitreous biopsy for: cytology to identify lymphoma cells; immunohistochemistry, flow cytometry and gene rearrangement studies to show monoclonality and mutations, such as *MYD88*, as well as excluding infectious agents.
- Systemic and CNS investigations, in collaboration with a haemato-oncologist.

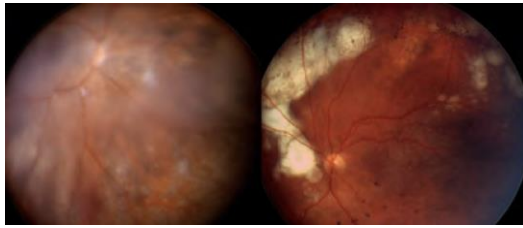
Management

There is no consensus on 'best treatment'. Most rely on [intravitreal methotrexate](#) injections, with [external beam radiotherapy](#) for resistant disease. Some authors advocate intra-vitreous [melphalan](#) or [rituximab](#) if other methods fail.

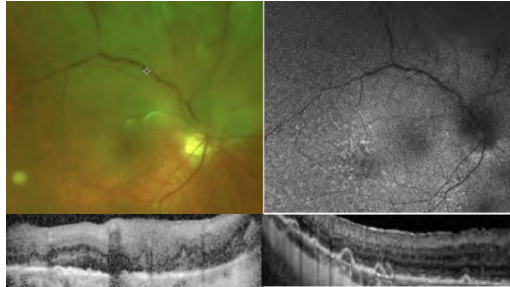
Damato and associates at the University of California, San Francisco, favour [an alternative approach](#), which hopefully prolongs life. This consists of:

- High-dose systemic chemotherapy followed by immunotherapy with lenalidomide or similar agents, administered by a haemato-oncologist.
- [Therapeutic vitrectomy](#) for dense vitreous infiltrates, which are resistant to systemic therapy

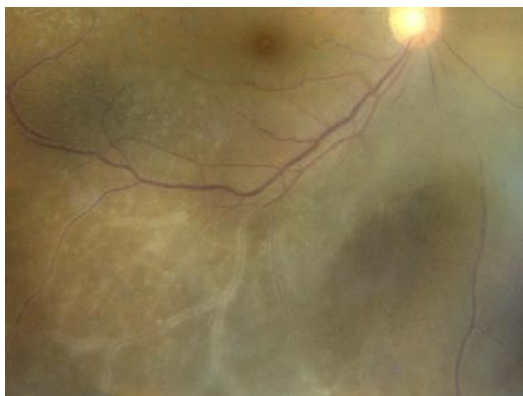
Patients require lifelong monitoring so that any ocular or CNS disease can be detected and treated promptly.



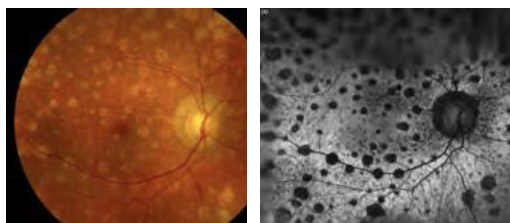
Bilateral vitreoretinal lymphoma, with infiltrates predominantly vitreal in the right eye and mostly sub-RPE in the left eye.



Vitreoretinal lymphoma. The colour image shows a diffuse retinal infiltrate and an intravitreal clump of lymphoma cells. FAF shows multiple hyper-autofluorescent sub-RPE deposits. OCT shows the intra-retinal infiltrate superior to the disc (left) and the sub-RPE deposits at the macula (right).

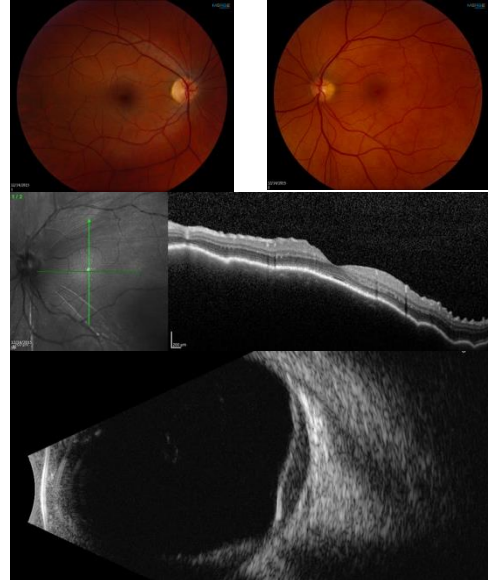

Vitreoretinal lymphoma with sheathing of retinal arterioles by lymphoma cells



Atrophic RPE spots, which are hypo-autofluorescent on FAF, corresponding to sites of previous sub-RPE lymphoma deposits

PRIMARY UVEAL LYMPHOMA



Primary uveal lymphoma of the left eye

[Primary uveal melanoma](#) is a rare disease, which tends to affect the choroid and/or ciliary body of one eye of an elderly patient, causing visual loss. It is usually a low-grade, extranodal marginal zone lymphoma with a good prognosis for survival.

On ophthalmoscopy, the choroid is pink, possibly with creamy lesions. ICG shows obscuration of the choroidal vasculature. OCT shows a diffuse uveal thickening with obliteration of the uveal blood vessels and a lumpy surface. Ultrasonography shows the lesion to have a low internal reflectivity and may reveal extraocular spread, which is common. The tumour may extend subconjunctivally, to form salmon pink nodules.

Management

Biopsy may be needed to confirm the diagnosis. Systemic investigation is indicated to exclude systemic disease.

This condition usually resolves with low-dose external beam radiotherapy.

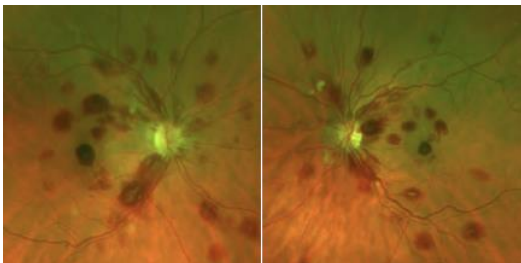
OTHER HEMATOLOGICAL MALIGNANCIES

These include:

Secondary intraocular lymphoma, leukaemia, cutaneous T-cell lymphoma, multiple myeloma, etc.

Clinical features include:

- tumour deposits in retina, vitreous, optic disc and choroid.
- Circulatory disturbances, causing retinal haemorrhages, cotton wool spots, venous tortuosity and microaneurysms.
- Exudation, such as optic disc oedema, exudative retinal detachment, and, in multiple myeloma, pars plana cysts.
- Infections, such as cytomegalovirus, toxoplasmosis, aspergillosis and cryptococcus.
- Extraocular abnormalities, such as proptosis, herpes zoster ophthalmicus, perilimbal infiltrates and graft-vs-host disease after allogeneic bone marrow transplantation.



Bilateral retinal haemorrhages and cotton-wool spots in a patient with leukaemia

PARANEOPLASTIC SYNDROMES

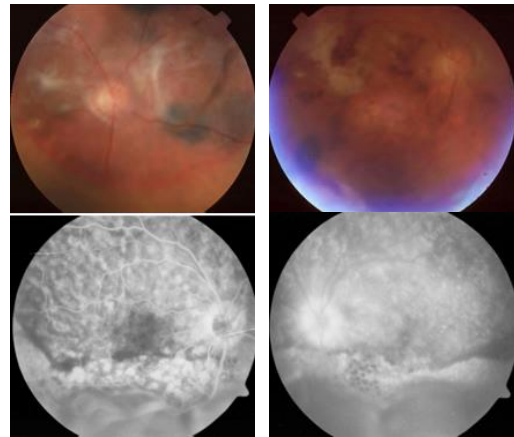
These include:

- [Melanoma-associated retinopathy \(MAR\)](#).
- [Cancer-associated retinopathy \(CAR\)](#).
- [Bilateral diffuse uveal melanocytic proliferation \(BDUMP\)](#).
- Miscellaneous other abnormalities (e.g., optic neuropathy and vitelliform lesions).

Symptoms include visual loss, night blindness, photopsia.

Signs of BDUMP include: (a) RPE stippling, red/grey patches, and depigmented areas; (b) attenuation and perhaps sheathing of retinal vessels; (c) optic atrophy; (d) multiple pigmented and amelanotic tumours; (e) vitreous cells; (f) exudative retinal detachment;

(g) cataract; and (h) glaucoma. Investigations include: (a) colour photography; (b) fluorescein angiography; (c) ultrasonography, including high-frequency examination of ciliary body; and (d) electrophysiology. Patients are referred to an oncologist for further investigation. An occult primary neoplasm can sometimes be detected only after repeated examinations.



Bilateral diffuse uveal melanocytic proliferation, with multiple pigmented choroidal lesions, diffuse uveal thickening, serous retinal detachment and rapidly progressive cataracts. The BDUMP resolved after surgical removal of a small cancerous tumour in the right lung.

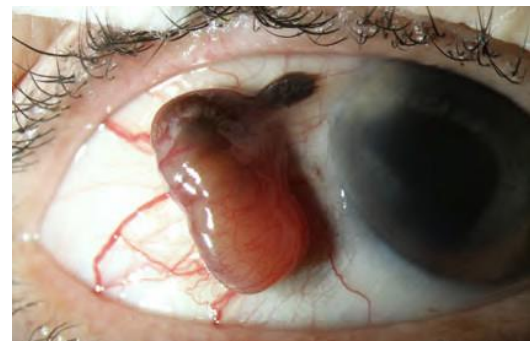Management

[Successful treatment of the primary tumour](#) can result in regression of the ocular disease.

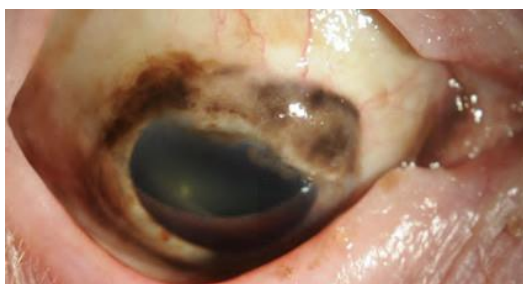Systemic steroids, plasmapheresis, and intravenous immunoglobulins can be tried but the results are unpredictable.

CONJUNCTIVAL MELANOMA

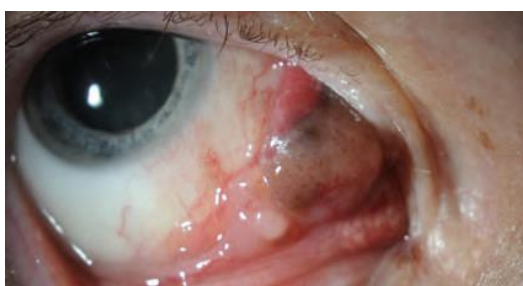[Conjunctival melanomas](#) are rare. They can arise in any part of the conjunctiva and can be nodular or diffuse, and pigmented or amelanotic, usually larger than naevi, with feeder vessels.



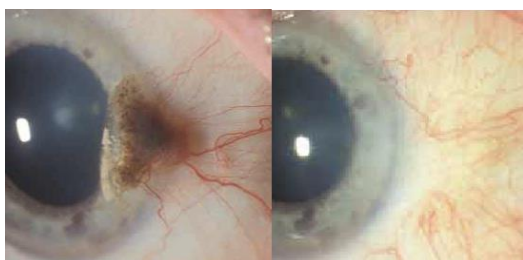
Nodular bulbar conjunctival melanoma in the right eye



Nodular melanoma arising from primary acquired melanosis



Right caruncular melanoma with melanotic and amelanotic areas. Despite successful ocular treatment the patient developed metastasis.



Conjunctival melanoma of the right medial limbus before and after treatment

Examination

The entire conjunctiva must be examined, and regional lymph nodes should be palpated. Biopsy must be excisional, using the no-touch technique, because incisional biopsy can cause tumour seeding, complicating subsequent management.

Management

Nodular melanomas are excised, using a no-touch technique. The [conventional practice is to excise the tumour with wide safety margins](#), apply adjunctive cryotherapy, then close the wound with an amniotic membrane graft, administering adjunctive radiotherapy and/or topical mitomycin C chemotherapy if histology indicates incomplete excision.

[An alternative approach, favoured by Damato, is to excise the tumour with narrow safety margins](#) using a no-touch technique; close the wound by primary intention (using fresh

instruments); administer adjunctive radiotherapy if the tumour is invasive, irrespective of histological clearance; and prescribe topical chemotherapy if there is primary acquired melanosis or histological evidence of pagetoid tumour spread. Proton beam or external beam radiotherapy may be useful for forniceal disease.

[Immune checkpoint inhibitors](#) may be useful in patients with advanced or resistant disease.

After treatment, patients require lifelong monitoring by an ophthalmologist, ensuring that the entire conjunctiva is examined.

At each postoperative visit, the regional nodes are palpated, and the patient is asked about general health.

[The benefits of sentinel lymph node biopsy are unproven.](#)

Any areas of confluent or increasing pigmentation are biopsied in case of recurrent disease. If enlarged regional nodes develop, the patient is referred to a head-and-neck surgeon for excision biopsy and radiotherapy. If there is any suspicion of systemic disease, the patient is referred to an oncologist.

[Risk factors for metastatic disease](#) include large tumour size and non-bulbar conjunctival involvement. [A TNM staging system](#) has been developed for these tumours and this has been [validated](#). The tumour is analysed for *BRAF* mutations in case treatment with vemurafenib or other *BRAF* inhibitors is ever needed. Conjunctival melanomas can respond to immune checkpoint inhibitors, unlike uveal melanomas.

[Guidelines for the management of patients with cutaneous melanoma](#) have been developed by a team of experts on behalf of the European Dermatology Forum (EDF), the European Association of Dermato-Oncology (EADO), and the European Organization for Research and Treatment of Cancer (EORTC). If these guidelines are followed in patients with conjunctival melanoma, those with less than a 5% risk of metastatic death at 10 years would undergo only clinical examination, with palpation of cervical, preauricular and submandibular nodes. Patients with a 5-15%

risk of metastatic death at 10 years would undergo lymph node ultrasonography, serum lactate dehydrogenase and serum S-100 analysis. Patients with a risk of metastasis that exceeds 15% at 10 years would in addition undergo computed tomography with intravenous contrast or positron emission tomography scans (PET CT) of the neck, thorax, abdomen and pelvis and magnetic resonance imaging with intravenous contrast of the brain.

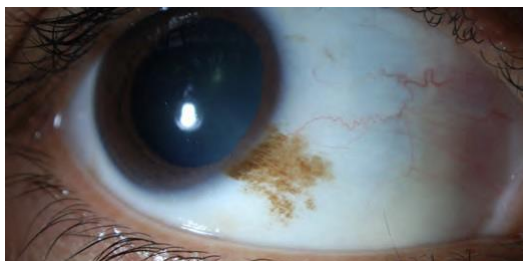
PRIMARY ACQUIRED CONJUNCTIVAL MELANOSIS (PAM)

The term [primary acquired melanosis](#) refers to the slit-lamp finding of conjunctival pigmentation not related to any systemic disease and not present at birth. According to the World Health Organisation Classification of Eye Tumors, the preferred histological term is [conjunctival melanocytic intraepithelial lesion \(CMIL\)](#).

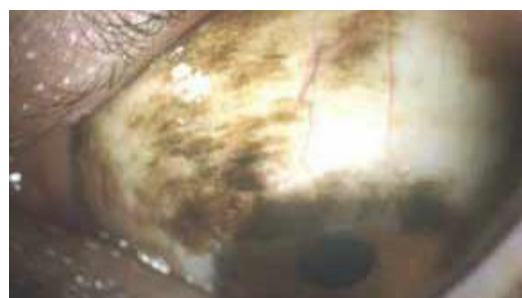Management

Biopsy of increasing or extensive PAM is required to categorise CMIL as low-grade, high-grade, or melanoma in situ to estimate the risk of invasive melanoma, which occurs in almost 50% of eyes with high-grade CMIL.

Samples are taken under local anaesthesia and are about 3 mm in diameter to provide an adequate specimen without the need for suturing. The degree of malignancy is estimated according to melanocytic density and atypia as well as the density of the tumour cells and the extent of their spread towards the conjunctival surface.



PAM, probably without atypia. Self-monitoring would be appropriate. Patients should ideally be provided with a photograph or shown how to take a picture of the lesion with their phone camera.

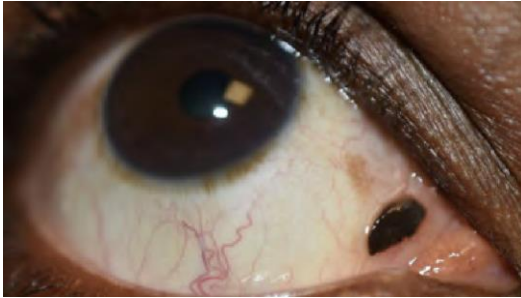

Extensive PAM requiring incisional biopsies to determine whether atypia is present.

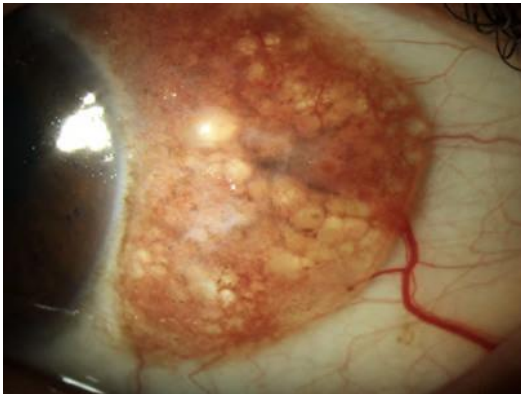
- If on slit lamp exam the PAM is limited to a small area of bulbar conjunctiva, the patient can be discharged with advice on self-monitoring. The patient can also be discharged if biopsy is performed and there is no atypia on histology.
- If the PAM shows moderate atypia, annual review by the local ophthalmologist would be prudent with biopsy if the melanosis increases.
- An unpublished study by Damato tentatively suggests that PAM involving the limbus likely to show atypia if it extends onto corneal surface.
- PAM with moderate or severe atypia is treated by removing as much of the lesion as possible and administering adjunctive topical 0.04% mitomycin c chemotherapy administered four times per day for 5 days per month for a total of 5 months. Steroid drops (e.g., fluorometholone) are administered to reduce discomfort. Patients need to be advised to wear gloves when administering drops, to apply vaseline to the lower eyelid to protect the skin, and to store soiled items in a special container, which must be returned to the hospital or family doctor for safe disposal. Some authors advocate digital compression of the lacrimal sac for five minutes when the drops are instilled, to prevent canalicular obstruction; however, these drops may reduce the risk of tumour seeding into the nasolacrimal sac and duct.
- Resistant disease can be treated with liquid nitrogen cryotherapy.
- After treatment for PAM with atypia, patients are monitored for recurrence, at the ocular oncology centre for 6-12 months, then at the local eye hospital. Biopsies are indicated only if the melanosis increases.

CONJUNCTIVAL NAEVUS

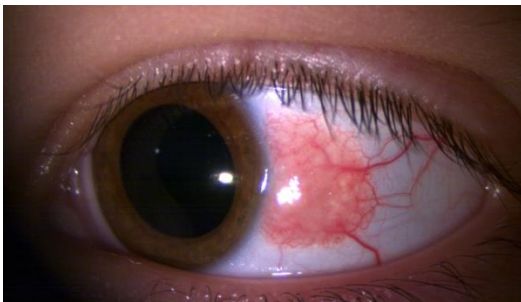[Conjunctival naevi](#) usually have clear cysts within them. They show varying degrees of pigmentation, which can change over time, and tend to grow in the first two decades of life. The risk of malignant transformation is less than 1%.



Naevus of the right plica



Giant bulbar naevus with multiple clear cysts



Amelanotic conjunctival naevus in a child

Management

Patients with small, bulbar conjunctival naevi can be advised on self-monitoring and discharged.

If the naevus is large and troublesome, it can be excised. An alternative treatment is yellow-laser (577nm) photocoagulation (300 microns, 80ms, 300-600MW) (Kapoor A, ISOO 2024).

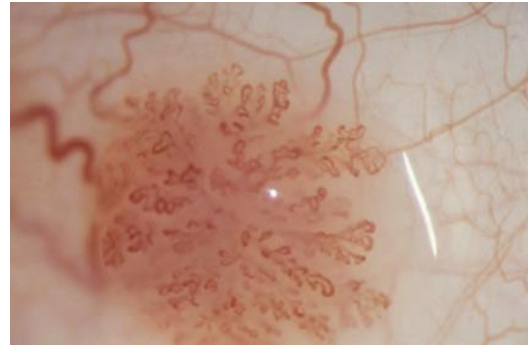
Children with conjunctival naevi are reviewed once a year. The parents should be advised that

it is normal for naevi to grow until the third decade of life. If surgery is indicated, the operation can be delayed until they are old enough for the operation to be performed under local anaesthesia.

Scope for tumour excision is greater with naevi involving non-bulbar conjunctiva because metastasis is more likely if malignant transformation ever occurs.

CONJUNCTIVAL PAPILLOMA

[Conjunctival papilloma](#) is diagnosed from its slit-lamp appearance and categorised as pedunculated or sessile and as single or multiple.



Conjunctival papilloma

It may not be possible to differentiate benign papilloma from papillary ocular surface squamous neoplasia.

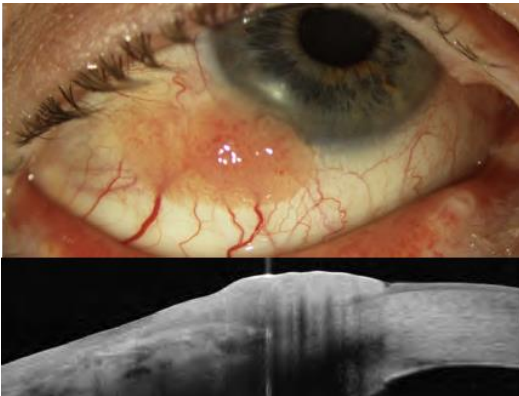
Management

Ideally, treatment is with topical and/or intralesional interferon; however, this is not currently available.

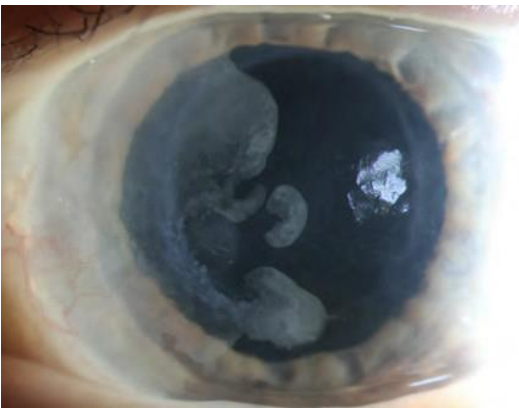
Excision is commonly followed by recurrence, despite using a no-touch technique. Neoadjuvant or adjunctive cryotherapy is therefore administered to reduce this risk.

OCULAR SURFACE SQUAMOUS NEOPLASIA

[Ocular surface squamous neoplasia \(OSSN\)](#) term includes 'conjunctival and corneal intra-epithelial neoplasia (CCIN)', 'conjunctival squamous intra-epithelial neoplasia (CSIN) and even invasive squamous cell carcinoma, even if confined to fornix and palpebral conjunctiva.



Conjunctival papillomatous carcinoma in situ. Excision biopsy is usually needed to exclude invasive carcinoma, but this patient was treated successfully with topical 5-FU alone because of his poor health.



Corneal squamous intra-epithelial neoplasia

Assessment

To differentiate this condition from a pagetoid variety of sebaceous carcinoma and from amelanotic melanoma, it is necessary to perform multiple biopsies, using immunohistochemistry.

Management

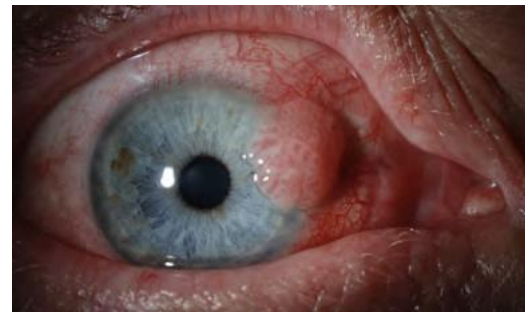
The standard treatment has been excision; however, because of the diffuse nature of this lesion, recurrences are common. Adjunctive [topical chemotherapy](#), consisting of 5-fluorouracil is therefore administered, reserving mitomycin-c for resistant cases. Interferon is not currently available.

Recently, there has been a trend towards [primary topical 1% 5-FU chemotherapy](#) administered four times daily for 2 weeks with the option for 2-weekly extension until tumour control is achieved. However, it [may not be possible to distinguish some cases from amelanotic conjunctival melanoma](#).

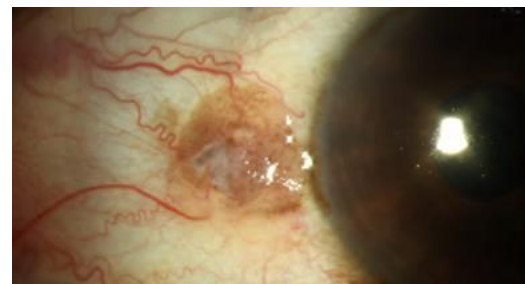Patients need to be advised to wear gloves when administering drops, to apply vaseline to the lower eyelid to protect the skin, and to store soiled items in a special container, which must be returned to the hospital or family doctor for safe disposal.

INVASIVE CONJUNCTIVAL CARCINOMA

The term '[conjunctival squamous carcinoma](#)' implies that the tumour is invasive, unless otherwise specified by the term 'in situ'.



Papillary conjunctival carcinoma



Pigmented squamous cell carcinoma in an African patient

Assessment

It is important to note whether the tumour is focal, diffuse or mixed. Anterior segment examination is performed to exclude intraocular spread, which causes glaucoma and pseudo-uveitis. The regional nodes are palpated.

Management

The standard treatment is local excision of any nodules. If the cornea is involved, the tumour is removed after devitalizing the epithelium with 95% alcohol. Bowman's layer is conserved as this is a barrier to intraocular spread. Adjunctive cryotherapy, radiotherapy or topical chemotherapy with 5-FU drops is administered to reduce the chances of recurrence.

[Systemic immune checkpoint inhibitors](#) (e.g., cemiplimab or pembrolizumab) may be effective in patients with resistant disease.

Advanced disease may require enucleation or exenteration.

Patients should be reviewed about 3 and 6 months after treatment, then every 6 months for 1-2 years, then once a year. Follow up should be lifelong as recurrence can occur after many years. The regional lymph nodes should be palpated at every visit.

The long-term surveillance can be undertaken at the patient's local eye hospital. In selected cases, it would be reasonable to discharge the patient with advice on self monitoring if the tumour was small and confined to bulbar conjunctiva.

SEBACEOUS GLAND CARCINOMA

[Conjunctival sebaceous gland carcinoma](#) can be primary or secondary to a meibomian [sebaceous gland carcinoma](#) in the eyelid. . This condition should be considered in any patient with unilateral blepharoconjunctivitis, especially if this does not resolve with standard treatment.

Management

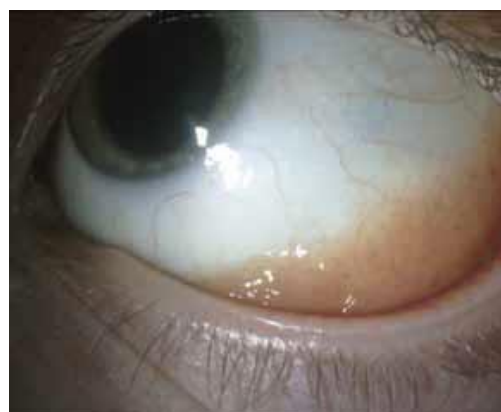Biopsy is necessary to confirm the diagnosis, using special lipid stains and immunohistochemistry. The regional nodes are palpated for metastases.

Surgical excision is not usually possible because the disease is extensive. [Success has been reported with topical Mitomycin-C chemotherapy, which may avoid the need for exenteration.](#) Life-long monitoring is needed.

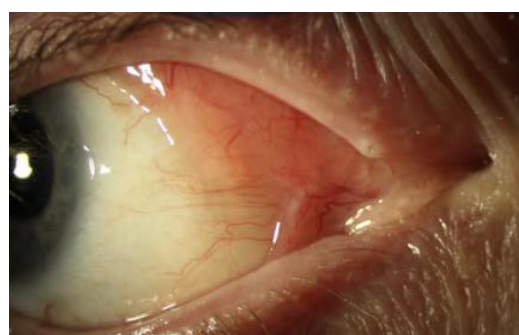[The mortality is about 10-30 percent.](#)

CONJUNCTIVAL LYMPHOMA

[Conjunctival lymphoma](#) usually presents as salmon-pink nodules, usually in the fornices and caruncular areas, often bilaterally. Symptoms include ocular discomfort, discharge and epiphora. Systemic disease occurs in about 2-5% either concurrently or at a later date.



Conjunctival lymphoma, with typical salmon-pink colour



Conjunctival lymphoma is often most prominent medially, around the plica

Assessment

Bilateral examination of the fornices is essential with palpation of the regional nodes.

Biopsy is required to confirm malignancy and to subtype the tumour. Most conjunctival lymphomas are of B-cell type, and the three most common are: (a) extranodal marginal zone B-cell lymphoma (i.e., MALT lymphoma); (b) follicle centre lymphoma; and (c) diffuse large cell lymphoma.

Pathological investigations include: (a) demonstration of monoclonality by immunohistochemistry and with the polymerase chain reaction technique; (b) characterization of type of lymphocytic proliferation (i.e., B cell vs T cell); and (c) assessment of tumour cell proliferation rate. It is advisable to consult the pathologist before doing the biopsy to ensure that the sample is handled correctly (e.g., samples in saline and in formalin).

The risk of systemic disease is higher with [bilateral disease](#). Other adverse factors include higher TNM T category, older age, female sex, elevated LDH, concurrent hepatitis C infection, and cell-cycle associated markers.

Management

If the diagnosis of lymphoma is confirmed, the patient is referred to a haemato-oncologist for systemic staging and treatment strategy.

[The standard treatment for low-grade conjunctival lymphoma is 20-30 Gy external beam radiotherapy.](#) After this treatment, patients will require management of their ocular surface disease. Some advocate no treatment; however, this may cause regret if systemic disease ever develops.

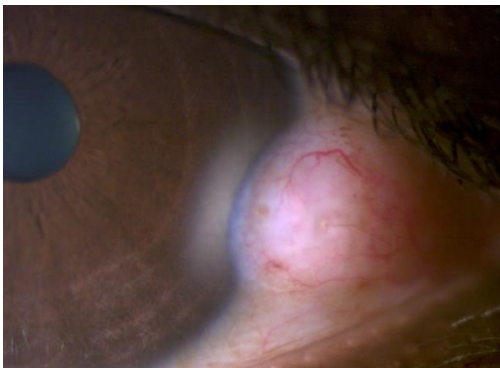
[Intralesional rituximab](#) has been reported as efficacious for local relapse.

[Systemic chemotherapy](#), in combination with [rituximab](#), is indicated for patients with high-grade conjunctival lymphoma or the presence of systemic disease.

Life-long follow-up at the patient's local eye hospital is conventional, but in selected cases it may be reasonable to discharge the patient with advice on self-monitoring.

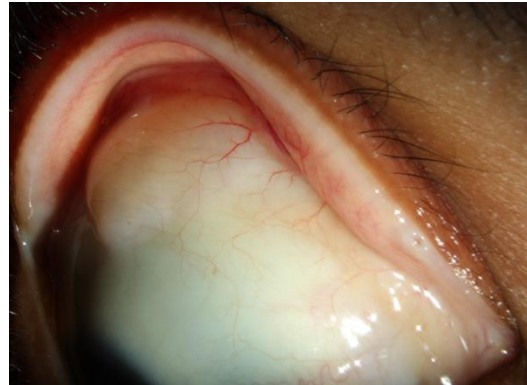
CHORISTOMA

A choistoma is a benign tumour containing tissue that is not normally present in the organ in which it has occurred.



Limbal dermoid

Troublesome [limbal dermoid](#) can be excised by lamellar dissection, being prepared to perform corneal or scleral grafting.



External angular dermoid

Excision of supero-temporal [dermolipoma](#) is avoided as this can be followed by ptosis, dry eye, and limitation of eye movements.

PATIENT REFERRAL TO GENERAL OPHTHALMOLOGIST BY OPTOMETRIST

Optometrists play an invaluable role in detecting and monitoring ocular tumours as well as counselling patients with these lesions.

As mentioned in the [guidelines of the College of Optometrists](#), practitioners should work within their scope of practice and, where necessary, seek further advice or refer the patient elsewhere.

EXAMINATION

FUNDUS LESIONS

- Dilated slit-lamp indirect biomicroscopy.
- Optical coherence tomography and/or autofluorescence imaging if possible.

ANTERIOR SEGMENT AND EXTRAOCULAR LESIONS

- Slit-lamp examination of the
 - entire conjunctiva, in selected cases also including fornices and palpebral conjunctiva.
 - anterior chamber, if possible, with gonioscopy if the lesion extends to the angle.

ALL LESIONS

- Baseline colour photography, giving the patient a copy of the photograph in case the next optometric assessment takes place elsewhere.
- Ideally, sequential photography to document or exclude tumour growth.
- A careful drawing of the lesion, with measurements and including nearby landmarks, if photography is not possible.

INDICATIONS FOR REFERRAL

- Any suspected intraocular or conjunctival malignancy.
- Benign tumours requiring treatment (e.g., symptomatic choroidal haemangioma,

retinal hemangioblastoma, vasoproliferative tumour, and conjunctival papilloma).

- Suspected paraneoplastic syndromes, such as bilateral diffuse uveal melanocytic proliferation (BDUMP).
- Pre-neoplastic conditions (e.g., melanocytoma, congenital ocular melanocytosis, primary acquired melanosis)

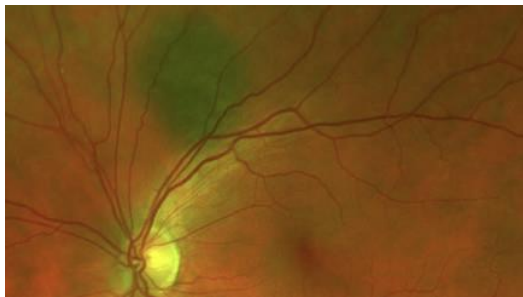
METHOD OF REFERRAL

- Advise all patients of the suspected diagnosis, emphasising the importance of not delaying or cancelling the hospital appointment.
- Instruct patients on what to do if an appointment is not received within a specified time. Give them a number to phone.
- Submit a colour photograph (and any other relevant images) of the lesion with the referral. If growth has been documented, the oldest and most recent images should be sent with the referral. These images may avoid the need for a hospital visit if they provide enough information for a report to be given remotely.
- State the suspected diagnosis and describe clinical findings explicitly (e.g., state actual size in mm or DD instead of writing 'large'). Also indicate the tumour location, including the quadrant (e.g., superior choroidal).
- Attach any investigation results including the pathology report if the tumour has been biopsied.
- To prevent delay, refer patients to the hospital eye clinic [directly](#) and not via the general practitioner, who should nevertheless be informed of the referral.

CONDITIONS NOT NEEDING REFERRAL

This section describes a few conditions that should not require referral to an ocular oncologist. However, if there is any uncertainty about the diagnosis or about the need for referral, it would be reasonable to send images of the lesion to an expert for advice.

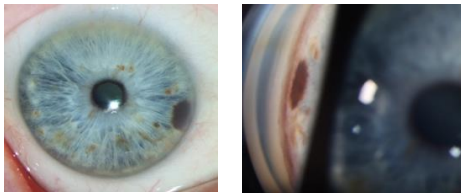
- Choroidal naevi with a MOLES score =0 (see section on choroidal naevus).



Common choroidal naevus (MOLES score = 0)

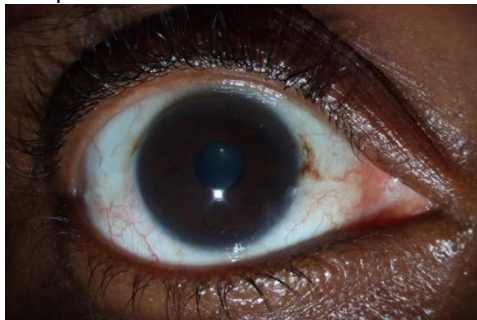
Choroidal naevi with a MOLES score of 1 or 2 should be referred to an ophthalmologist non-urgently, whereas melanocytic tumours with a MOLES score of 3 or more should be referred urgently, following the 'suspected cancer' protocol.

- Nodular iris naevi with a diameter <4 mm and thickness <1 mm unless growth has been documented.



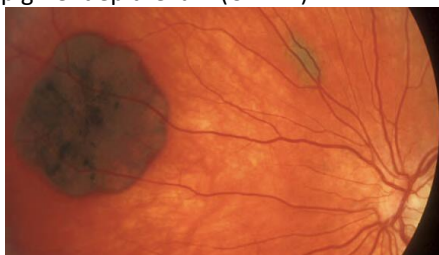Typical iris naevus

- Complexion-associated melanosis



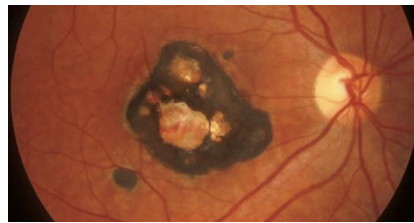
Complexion-associated melanosis

- Congenital hypertrophy of the retinal pigment epithelium (CHRPE).



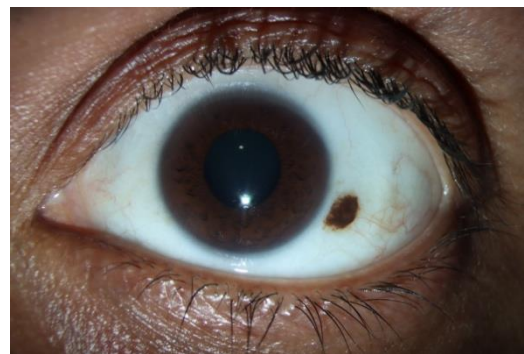
Congenital hypertrophy of the RPE

- Chorioretinal scars.



Chorioretinal scar with discrete, irregular margins

- Small, bulbar conjunctival naevus that can reliably be self-monitored by patient.



PATIENT REFERRAL TO OCULAR ONCOLOGIST

As a general principle, patients should receive care as close to their home as possible. The UK is fortunate, however, to have supraregional ocular oncology centres in Glasgow, Liverpool, London, and Sheffield. Some hospitals, such as Oxford Eye Hospital, provide a regional ocular oncology service to reduce the need for patients with ocular tumours to travel to distant centres for diagnosis and follow up unless specialist care is needed.

Referring ophthalmologists should follow [guidelines of the Royal College of Ophthalmologists](#).

INDICATIONS FOR REFERRAL

- Suspected intraocular or conjunctival malignancy (e.g., ocular melanoma, suspected conjunctival intraepithelial neoplasia with atypia, conjunctival carcinoma).
- Benign tumours requiring specialist treatment (e.g., symptomatic choroidal haemangioma, retinal hemangioblastoma, vasoproliferative tumour, and conjunctival papilloma) or investigations (e.g., ultrasound biomicroscopy, biopsy) if not possible or available at local hospital.
- Suspected paraneoplastic syndromes, such as bilateral diffuse uveal melanocytic proliferation (BDUMP).

METHOD OF REFERRAL

- Advise all patients of the suspected diagnosis, emphasising the importance of not delaying or cancelling the hospital appointment.
- Instruct patients on what to do if an appointment is not received within a specified time. Give them a number to phone.
- Submit a colour photograph (and any other relevant images) of the lesion with the referral. If growth has been documented, the oldest and most recent images should be sent with the referral. These images may avoid the need for a hospital visit if they

provide enough information for a report to be given remotely by an ophthalmologist.

- Do not delay the referral because investigations or results are awaited.

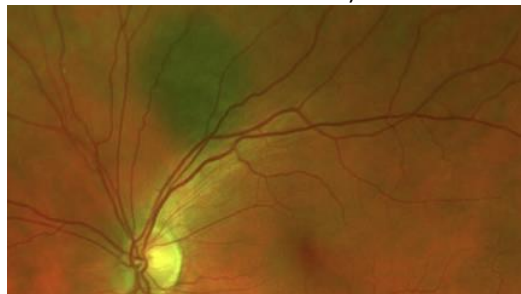
CONDITIONS NOT NEEDING REFERRAL

This section describes a few conditions that should **not** require referral to an ocular oncologist.

Lesions not needing treatment and which can safely be monitored at the local hospital should not be referred to an ocular oncology centre unless growth is documented.

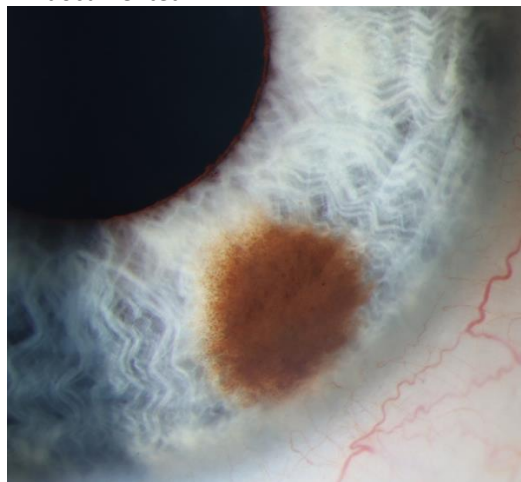
However, if there is any uncertainty about the diagnosis or about the need for referral, it would be reasonable to send images of the lesion to an ocular oncologist for advice.

- Choroidal naevi with a MOLES score <3 (see section on choroidal naevus).



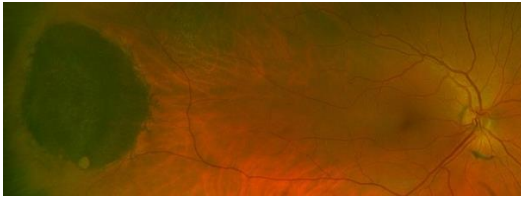
Common choroidal naevus (MOLES score = 0)

- Iris naevus, unless growth has been documented.



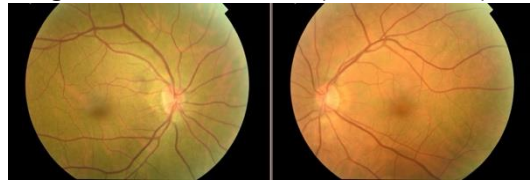
Iris naevus

- Congenital hypertrophy of the retinal pigment epithelium (CHRPE).



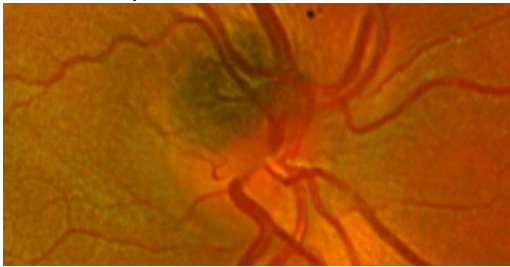
Congenital hypertrophy of the RPE

- Congenital ocular melanosis (Naevus of Ota)



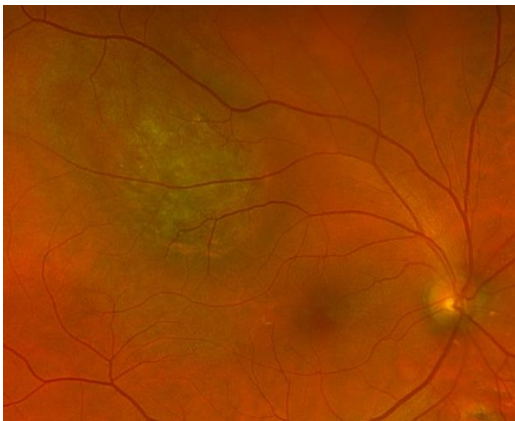Congenital ocular melanosis

- Melanocytoma.



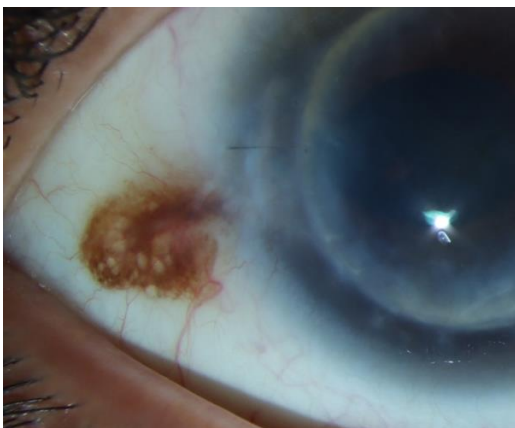Optic disc melanocytoma

- ‘Dry’, asymptomatic choroidal haemangioma



Circumscribed choroidal haemangioma

- Conjunctival naevus



Conjunctival naevus with cysts

MONITORING

Monitoring should ideally be offered to patients as close to their home as possible. This would be more convenient and less expensive for them especially if they live far from an ocular oncology centre.

For example, patients with the *BAP1* tumour-predisposition syndrome, congenital ocular melanocytosis (naevus of Ota), melanocytoma, atypical choroidal naevus, von Hippel Lindau disease, *DICER1* syndrome, and other predisposing conditions should be monitored at their local hospital and referred to an ocular oncology centre only if a tumour is suspected or found.

Patients with common naevi and other lesions with only a minimal risk of malignant growth or transformation can be monitored by their community optometrist, unless the lesion is difficult to examine.

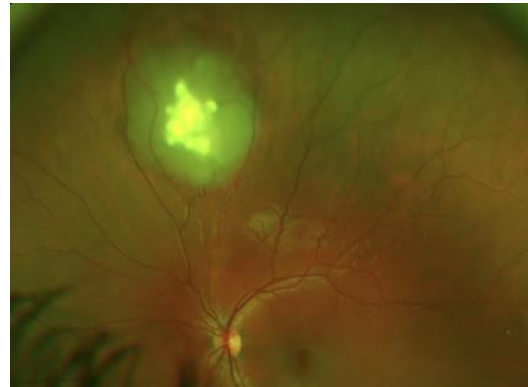
Patients can be left to self-monitor low-risk lesions, using a mirror or their phone camera, if these lesions are easily visible (e.g., bulbar conjunctival naevi and small areas of melanosis).

Nevertheless, ophthalmologists and optometrists are welcome to request expert advice regarding frequency and method, if necessary. Images of the lesion and any relevant information would improve the quality of the report.

INDICATIONS

Surveillance for development of new lesions

- Primary ocular tumours in patients with VHL (retinal angioma), *DICER1* (medullo-epithelioma), congenital ocular melanosis (melanoma), and *BAP1* tumour predisposition syndrome (uveal melanoma).
- Recurrent ocular tumours (e.g., after treatment of uveal melanoma).
- Malignant transformation (e.g., melanocytoma, naevus, retinoma/retinocytoma, CHRPE).



Retinocytoma in a child, with internal calcification. This lesion, if not treated, needs life-long monitoring in case malignant growth ever occurs.

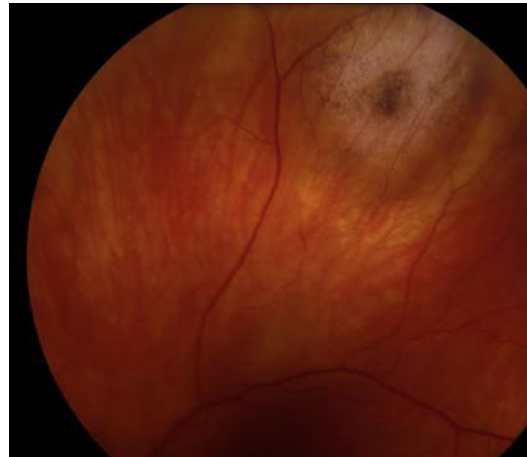
- Systemic malignancy in patients with conditions such as uveal metastasis; ocular paraneoplastic disease (e.g., BDUMP; retinal angioma from VHL, multiple CHRPE lesions (suggesting polyposis coli); familial uveal melanoma (*BAP1* tumour predisposition syndrome), and ocular lymphoma in a patient with systemic or CNS disease.
- Metastatic disease in patients with uveal melanoma (especially liver), conjunctival cancers (especially regional nodes), etc.
- Psychological morbidity needing expert care, especially in patients with poor life expectancy (e.g., uveal melanoma), loss (e.g., of vision), disfigurement (e.g., after enucleation), etc.
- Side-effects and complications of treatment (e.g., radiation retinopathy, uveitis, glaucoma). tumour progression (e.g., naevus growth, osteoma extension, retinal detachment from choroidal haemangioma, necrosis of melanocytoma).
- Ocular side-effects of systemic treatment for cancer.

Monitoring of known lesions

- Common choroidal naevi (MOLES = 0). Patients should be reviewed every 1-2 years, ideally with sequential colour photography, because very early uveal melanomas can be indistinguishable from common naevi, albeit rarely. OCT and FAF would enable subretinal fluid and lipofuscin

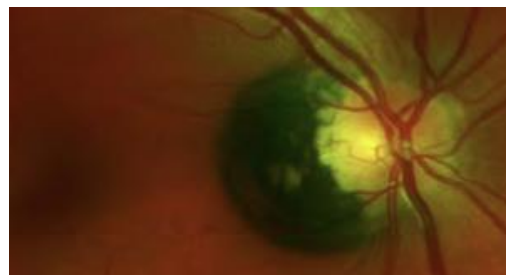
to be detected with greater sensitivity. Ultrasonography is not required. These should be monitored by a community optometrist. The patient should be given a photograph of the lesion to take to the optometrist at every visit.

- Low-risk choroidal naevi (MOLES = 1). These ideally require colour photography, OCT and FAF at baseline, then after 6 months, then every 12 months, indefinitely. In some hospitals, such as Oxford Eye Hospital, these patients attend the photography unit for imaging, which is then assessed remotely by an ophthalmologist in a 'virtual clinic', unless the lesion extends beyond the range of the camera, in which case the patient is seen in person in a 'face-to-face' ocular oncology clinic.
- If the patient prefers to attend a community optometrist for long-term surveillance, measures that can be taken to enhance safety include:
 - Giving the patient a photograph of the lesion to take to the optometrist at every visit.
 - Giving the patient an information sheet with advice on what care to expect (e.g., receiving a photograph of the lesion at every visit) and on what to do if any problems arise (e.g., with contact details of the hospital eye clinic).
 - Organising fail-safe appointments at the hospital, which can be cancelled or postponed if a satisfactory report (ideally with an image of the lesion) is received from the optometrist.
- High-risk choroidal naevi (MOLES = 2). These ideally require colour photography, OCT and FAF at baseline, then every 6 months for 1-2 years, then once a year, indefinitely, with in-person or remote assessment by an ophthalmologist, depending on whether or not the entire lesion can be included in colour photographs for remote assessment.



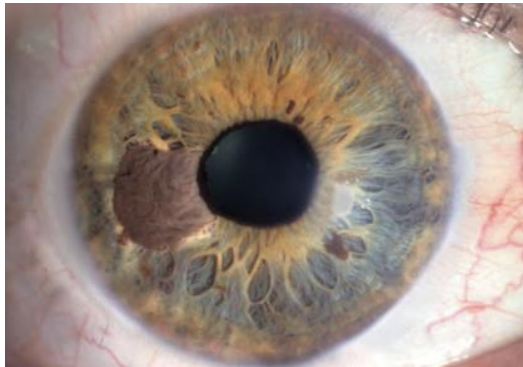Amelanotic choroidal naevus (MOLES = 00100 = 1).

- Congenital hypertrophy of the retinal pigment epithelium (CHRPE). Review every two years by a community optometrist is indicated because of the (extremely) low risk of adenoma or adenocarcinoma and in case of mistaken diagnosis. If the lesion is too peripheral to photograph, a detailed drawing of the lesion may suffice.

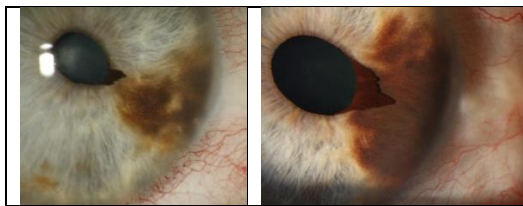


CHRPE lesion, which in this case is unusual because of its juxta-papillary location.

- Iris naevi, if suspicious (i.e., >3 mm in diameter), should be reviewed by an ophthalmologist after 6 months, then every year, comparing slit-lamp appearances with a baseline colour photograph. Gonioscopy is indicated if the tumour involves the angle. Ciliary body spread is detected with UBM or, less reliably, if this US is not possible, by noting sentinel vessels.

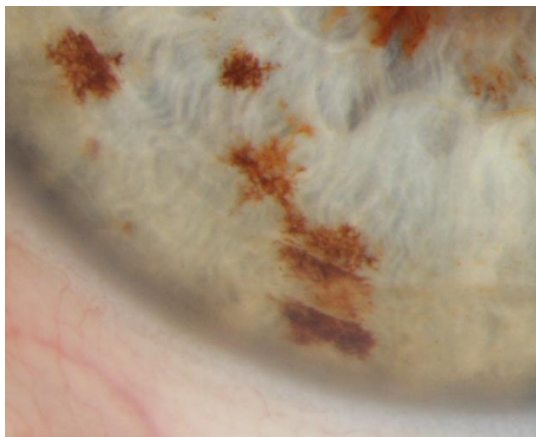


Monitoring by an ophthalmologist is indicated for iris naevi that are more than 3 mm in diameter or involving angle



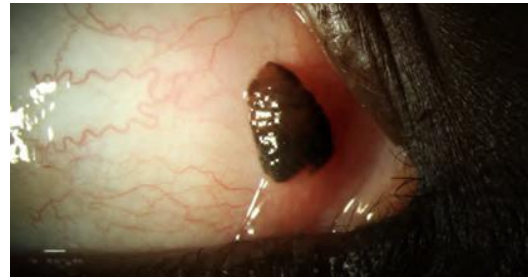
Growth of an iris melanoma

- Iris freckles do not require any monitoring unless they cannot reliably be differentiated from naevi. Freckles tend to form a 'canopy' of pigmented cells on the iris surface, unlike naevi which disturb the iris anatomy.



Freckles, which overlie the iris, without disturbing the underlying anatomy

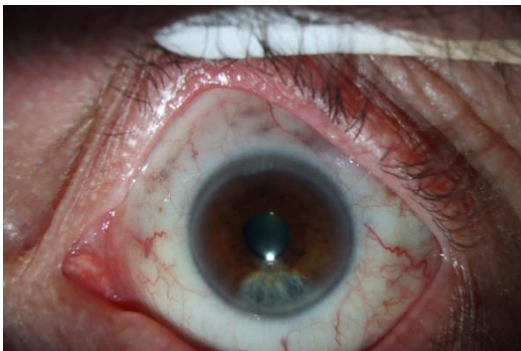- Iridociliary cysts can be monitored by optometrists, who should be able to detect glaucoma and cataract if these ever develop.
- Conjunctival naevi can undergo malignant transformation, albeit rarely (< 1% cases). The decision as to whether a particular naevus should be monitored by the patient (e.g., using a phone camera), a community optometrist or an ophthalmologist will depend on the size and location of the lesion.



Conjunctival naevi require surveillance by an optometrist or ophthalmologist if self-monitoring is difficult because of their location or if differentiation from melanoma is uncertain or if the naevus involves non-bulbar conjunctiva where any malignant transformation is associated with an increased risk of metastasis.

- Primary acquired conjunctival melanosis if limited to a small area (i.e., diameter < 5 mm) can be monitored locally, with referral to an ocular oncologist only if the pigmentation becomes more extensive. Patients with a small area of perilimbal pigmentation can self-monitor (alone or in addition to any surveillance by an ophthalmologist or optometrist), using a mirror or camera. As with other lesions, baseline photography of the lesion is ideal.
- Choroidal haemangiomas, whether treated or untreated, do not require any monitoring if 'dry' and asymptomatic if the patient can be relied upon to attend an optometrist if the vision ever becomes blurred or distorted, so that the optometrist would urgently refer the patient to an ophthalmologist if any retinal detachment is detected.
- Choroidal osteomas not involving the fovea need monitoring by an ophthalmologist with sequential photography in case PDT is indicated because of growth threatening vision. Patients should be advised to present immediately if they develop symptoms, in case a neovascular membrane requires urgent treatment.
- [Eccentric disciform](#) lesions, also known as 'peripheral exudative haemorrhagic chorioretinopathy', usually regress after a few weeks. The patient should be reviewed by an ophthalmologist after 2-3 months when they can be discharged if vitreous haemorrhage has not occurred and if the macula is not threatened by exudates, haemorrhages, or retinal detachment.

- von Hippel Lindau syndrome requires ophthalmic monitoring by an ophthalmologist every six months from the age of 1 year until the age of 30 years, and then once a year indefinitely because of the risk of retinal hemangioblastomas, which resemble microaneurysms when small.
- Melanocytoma is a high-risk naevus, requiring life-long monitoring (i.e., annual review) by an ophthalmologist. Some of these lesions can show limited growth.
- Congenital ocular melanocytosis can be regarded as a high-risk naevus requiring surveillance by an ophthalmologist. It is important to exclude ciliary body melanoma, looking for episcleral sentinel vessels if high-frequency ultrasonography is not available.



Congenital ocular melanosis of the left eye requires monitoring for uveal melanoma

These recommendations are only tentative as there is no consensus amongst ocular oncologists on monitoring. As mentioned, if any concerns or uncertainties ever arise, images of the lesion can be sent to an ocular oncologist for expert opinion.

COUNSELLING

- Ophthalmologists should provide all necessary information and guidance, emotional support and reassurance, not only to patients but also accompanying persons.
- It is also essential to provide advice the family doctor as well as any specialists involved in the patient's care (e.g., medical oncologist, geneticist).

FOLLOW-UP BY LOCAL OPHTHALMOLOGIST

In general, patients should be reviewed at their local hospital approximately:

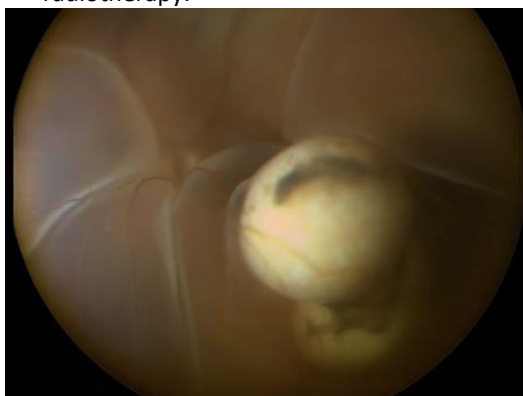
- 1 week after any intraocular procedure (e.g., trans-scleral local resection, endoresection, vitrectomy, intraocular triamcinolone injection).
- 1 month after extraocular treatment (e.g., plaque radiotherapy, enucleation, conjunctival tumour excision).

The discharge letter from the ocular oncology centre will propose a follow-up schedule for each individual patient, with advice on problems that are most likely to occur.

IMMEDIATE POST-OPERATIVE PERIOD

The most likely problems are:

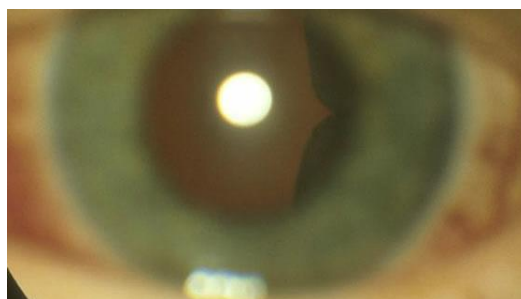- Raised intraocular pressure after vitrectomy, intravitreal steroid injection, or topical steroid therapy.
- Rhegmatogenous retinal detachment after local resection of an intraocular tumour.
- Endophthalmitis after any intraocular procedure.
- Orbital cellulitis after enucleation
- Hypotony after iridocyclectomy or cyclochoroidectomy.
- Severe exudative retinal detachment after radiotherapy.



Severe exudative retinal detachment after proton beam radiotherapy of a choroidal melanoma, which was successfully treated by endoresection of the 'toxic tumour'. Alternatively, intravitreal anti-VEGF injection may be successful.

- Corneal dellen after treatment of a medial conjunctival or intraocular tumour.
- Diplopia after extraocular muscle disinsertion.

- Allergy to any topical medications.
- Adverse reactions to any oral medications.
- Conjunctival dehiscence after conjunctival tumour excision or plaque radiotherapy. Irradiated sclera can melt if exposed, so that urgent conjunctival repair is indicated if dehiscence occurs.
- Uveal effusion after plaque radiotherapy for choroidal melanoma, a rare but potentially serious problem.

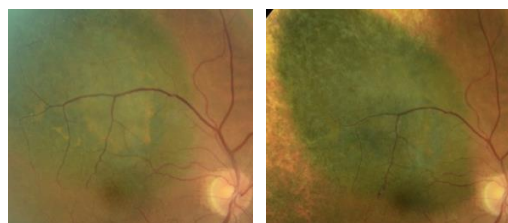


Uveal effusion after plaque radiotherapy for choroidal melanoma, a rare but potentially serious problem

LONG-TERM TUMOUR MONITORING

As a rule, patients are reviewed every 6 months for four or five years, then annually.

- Local recurrence of posterior uveal tumour is best identified by sequential photography, noting lateral extension of margins towards adjacent landmarks or the appearance of greater bulk.



Recurrent choroidal melanoma following plaque radiotherapy. Note the tumour growth towards the optic disc.

[Ultrasonographic detection of tumour growth is rare in the absence of other signs.](#) Thickness should be measured from the internal scleral surface, excluding retina. Any apparent increase in thickness not exceeding 0.5mm should be regarded as measurement variation and the

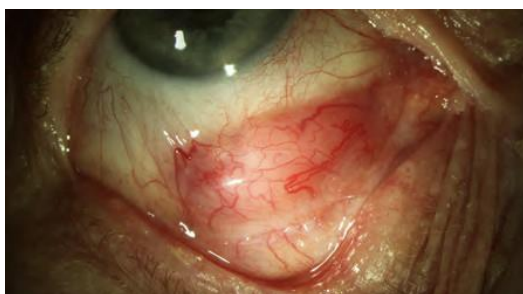examination should be repeated several months later. Ultrasonography is also useful for detecting extraocular recurrence (which is rare). Life-long monitoring is ideal as tumours can recur many years after treatment (albeit rarely).

- Local recurrence of iris melanoma is detected by slit-lamp examination and gonioscopy, aided by sequential imaging.



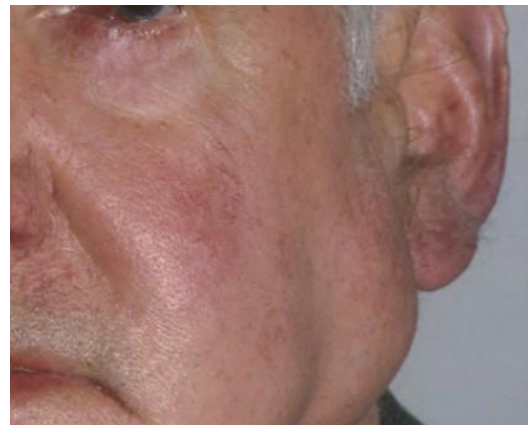Recurrent iris melanoma following proton beam radiotherapy

- Local tumour recurrence of intraocular metastasis is rare after radiotherapy and more common after other forms of treatment. Surveillance is performed as for uveal melanoma, but more frequently because metastases grow more rapidly.
- Local recurrence of a conjunctival tumour should be detectable by slit-lamp examination. It is essential to examine the entire conjunctiva, including the fornices.



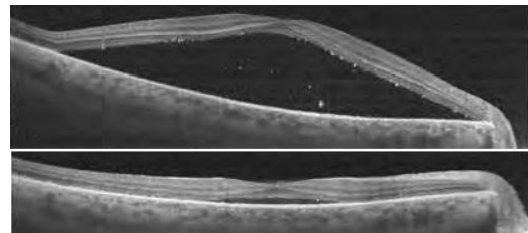
Recurrent conjunctival melanoma in inferior fornix

- Regional nodal metastases after treatment of a conjunctival tumour should be excluded by palpating local lymph nodes at every visit.



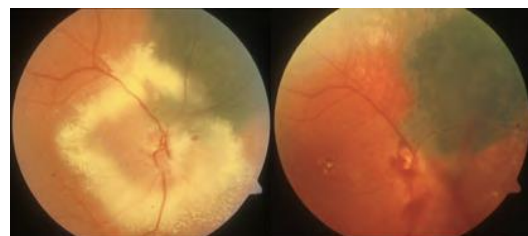
Pre-auricular metastasis from conjunctival melanoma

- Metastases from uveal melanoma are best detected by liver imaging (e.g., US or MRI).
- Macular oedema and epiretinal membranes are detected by visual acuity testing and OCT.



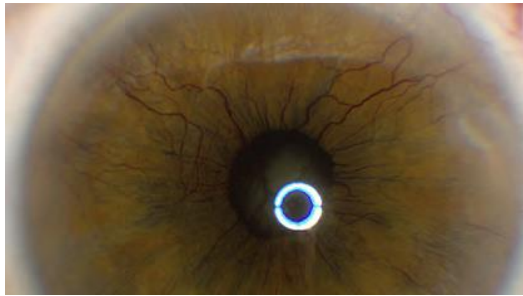
Serous retinal detachment after proton beam radiotherapy of a superior choroidal melanoma in the right eye (upper image), successfully treated by transpupillary laser therapy to the irradiated tumour after unsuccessful anti-VEGF therapy and photodynamic therapy (lower image)

- Radiation optic neuropathy needs close monitoring in case disc new vessels and neovascular glaucoma develop.



Optic neuropathy after proton beam radiotherapy of a juxtapapillary choroidal melanoma in the right eye, showing exudation (left) and, later, neovascularisation with vitreous haemorrhage in the same eye (right)

- Exudative retinal detachment after brachytherapy or proton beam radiotherapy usually resolves spontaneously after a few months but may cause neovascular glaucoma if prolonged or severe.



Iris neovascularisation after proton beam radiotherapy for choroidal melanoma. This usually causes neovascular glaucoma requiring enucleation

- Cataract is not uncommon after ocular radiotherapy or intraocular surgery. It is diagnosed in the usual manner.
- Glaucoma can be caused by steroid treatment, vitrectomy and iris neovascularization and requires gonioscopy, as with other causes.
- Diplopia can occur after extraocular muscle disinsertion during plaque or tantalum marker insertion. This usually resolves spontaneously, especially if there is binocular single vision in any direction of gaze.
- Vitreous haemorrhage is common after trans- retinal tumour biopsy and usually resolves spontaneously. After trans-scleral local resection ('exoresection'), vitreous haemorrhage indicates a retinal tear requiring urgent treatment.
- Corneal dellen can develop if the medial bulbar conjunctiva is swollen. This responds to antibiotic ointment applied frequently.
- Scleral melt is a serious complication and can occur if irradiated sclera is exposed (e.g., after conjunctival wound dehiscence). A scleral graft is usually necessary. Some prefer autologous grafts from another part of the same eye.
- Limbal stem cell deficiency can follow radiotherapy or topical chemotherapy.
- Keratopathy can be caused by keratinization of the superior tarsal conjunctiva following proton beam radiotherapy if the upper eyelid margin is included in the radiation field. The patient (or a relative or carer) may be able to wipe the keratin away from the tarsal conjunctiva with a cotton bud.

DIAGNOSTIC AND THERAPEUTIC PROCEDURES AT LOCAL HOSPITAL

There are several procedures that could be undertaken safely at the patient's local hospital.

Before any intervention, advice can be obtained from an ocular oncologist, if necessary. In any case, it would be ideal if the ocular oncology centre could be informed about any procedures that are performed on patients previously treated at that centre, for audit purposes. If any tumour tissue requires histology (e.g., after incisional biopsy of primary acquired melanosis) the pathologist at the local hospital should ideally send the specimen to a specialist ophthalmic pathologist at the ocular oncology centre for primary reporting.

CATARACT SURGERY

It should be possible to perform phacoemulsification in the usual manner. Care should be taken if zonules are deficient following iridocyclectomy. Previously treated iris or posterior-segment melanoma is not a contraindication to cataract surgery if the likelihood of active tumour is minimal. This estimate can be provided by an ocular oncologist on request.

Mapping conjunctival biopsies may be performed to exclude minimal residual disease in patients previously treated for conjunctival malignancy.

GLAUCOMA SURGERY

Glaucoma can be managed in the usual manner. If the patient has been treated for an iris or posterior uveal melanoma. If the tumour is sterile, it should be safe to perform a drainage procedure, including the insertion of a Baerveldt or another implant. Painful neovascular glaucoma usually requires enucleation.

STRABISMUS SURGERY

Ocular motility disorders can follow muscle disinsertion performed during plaque or

tantalum marker insertion or during trans-scleral local resection.

The muscle surgery can be difficult because of extensive scarring surrounding the muscle and adhering the conjunctiva to the sclera. One method of overcoming these difficulties is to shave the conjunctiva (and perhaps also the extraocular muscle together with surrounding scar tissue), away from the sclera with a Bard-Parker scalpel, advancing or recessing the muscle and surrounding scar tissue as needed.

Radiotherapy can make the conjunctiva friable and the sclera soft and delicate.

After trans-scleral resection, the sclera may be extremely thin in the region of a lamellar scleral flap and may be located beneath the muscle insertion.

Special care must be taken to close the conjunctiva over irradiated sclera, which may melt if exposed, possibly because of wound dehiscence.

TREATMENT FOR MACULAR OEDEMA

Macular oedema is a common problem after radiotherapy. This is usually treated with intravitreal injections of anti-angiogenic agents (e.g., bevacizumab, ranibizumab, aflibercept) or anti-inflammatory drugs (e.g., triamcinolone).

A common protocol is to administer bevacizumab once a month for three months before reassessing the patient and continuing this treatment only if an objective response is demonstrated with OCT and by measuring the visual acuity.

The response to these agents varies greatly between patients. Anti-VEGF therapy will probably not improve the visual acuity if:

- OCT shows retinal receptor atrophy or
- if the fovea has received a high dose of radiation, which is likely if the posterior tumour margin extends to within two 2mm of the fovea, or if

- OCT angiography shows disruption of the foveal avascular zone.

Care must be taken to avoid retinal damage if a bulky tumour is present (e.g., after radiotherapy).

In some cases, the oedema recurs when this treatment is stopped so that therapy needs to be continued indefinitely.

We have successfully treated a few patients with resistant macular oedema by administering transpupillary thermotherapy or photodynamic therapy to the irradiated tumour.

TREATMENT FOR EXUDATIVE RETINAL DETACHMENT

Serous retinal detachment is most likely to develop after radiotherapy of large choroidal melanomas and can develop rapidly. This '[toxic tumour syndrome](#)' may respond to intravitreal anti-angiogenic therapy (especially aflibercept, in our experience, or steroids), using a corneal contact lens to see the detached retina when injecting the drug to avoid causing iatrogenic rhegmatogenous retinal detachment.

Exudative retinal detachment can sometimes be successfully treated by removing the 'toxic tumour' by endoresection or exoresection depending on its size and location.

PREVENTION OF TOXIC-TUMOUR SYNDROME

When toxic tumour syndrome is considered likely, because of large tumour size or extensive retinal detachment, it has recently become routine practice to administer prophylactic anti-VEGF therapy, such as intravitreal bevacizumab, administered at the time of radiotherapy (e.g., plaque insertion or tantalum marker insertion, plaque removal, or biopsy after completion of radiotherapy) and then every 2-3 months for two years.

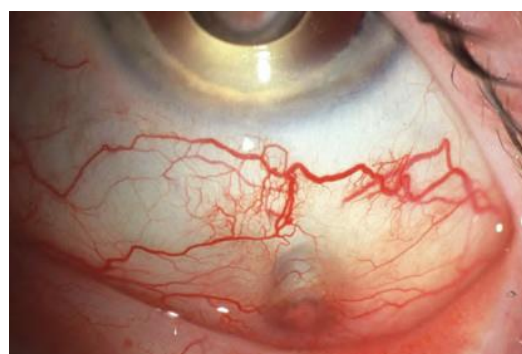
ENUCLEATION

Enucleation is performed in the usual manner, with surgeons using their preferred orbital implant. Care must be taken not to touch any

extraocular tumour nodule, to avoid seeding into the orbit. If the eye is removed for uveal melanoma, genetic typing of the tumour may be useful for prognostication. Fresh or frozen tissue provides better results than formalin-fixed tissue.

REMOVAL OF EXTRUDING TANTALUM MARKER

Tantalum markers threatening to extrude through the overlying conjunctiva should if possible be removed before the conjunctiva ulcerates. Irradiated conjunctiva may be friable, also healing slowly.



Tantalum marker under irradiated conjunctiva following proton beam radiotherapy for choroidal melanoma. Removal of the marker is indicated because of a high risk of conjunctival ulceration and scleral melt. The problem is now avoided by placing markers out of the radiation field.

BIOPSY OF CONJUNCTIVAL PRIMARY ACQUIRED MELANOSIS

Incisional biopsy is required to detect atypia. The procedure is performed under topical anaesthesia. Elliptical biopsies are approximately 3 mm long to provide sufficient tissue for histology without requiring suturing. The specimen should be grasped at one point only, to minimise crush artefact. The tissue should be gently placed onto a paper card to avoid scrolling of the specimen. The sample should be transported to the laboratory in formalin.

Incisional biopsy is contraindicated for nodular tumours, because of the risk of seeding tumour cells around the conjunctiva.

EXCISION BIOPSY OF NODULAR CONJUNCTIVAL TUMOURS

Malignant nodular conjunctival tumours are best excised by ocular oncologists. If this is not possible, our preferred method is as follows:

- Inject local anaesthetic with adrenaline, without the needle touching the tumour, or instil anaesthetic drops, with sedation.
- Apply a continuous line of bipolar cautery 2 mm around the tumour margins.
- Excise the tumour, cutting within the cautery line, using blunt-tipped spring scissors, following a no-touch technique and ensuring meticulous haemostasis.
- If the tumour involves cornea, scrape the tumour towards the limbus, after devitalizing the corneal epithelium with 95% alcohol so that it separates easily from Bowman's membrane, which must not be damaged as it is a barrier to intraocular spread.
- Shave the tumour away from the limbus with a Bard Parker scalpel, resecting circumferentially.
- Place the specimen on a card and into formalin, without crushing the tissue with the forceps, marking the card (e.g., by snipping a notch on the card) to orientate the specimen for the pathologist.
- Close the conjunctiva, using fresh instruments, after undermining the conjunctiva widely (i.e., as far as the fornices, avoiding muscle damage).

VITREORETINAL LYMPHOMA BIOPSY

Discuss the biopsy with the pathologist before the procedure so that the laboratory can prepare for analysis and provide the required transport medium. A large, undiluted vitreous sample is needed. If transported without fixation it must arrive at the laboratory within an hour.

CATARACT SURGERY

It should be possible to perform phacoemulsification in the usual manner. Care should be taken if zonules are deficient following iridocyclectomy. Previously treated iris or posterior-segment melanoma is not a contraindication to cataract surgery if the likelihood of active tumour is minimal. This

estimate can be provided by an ocular oncologist on request.

Mapping conjunctival biopsies may be performed to exclude minimal residual disease in patients previously treated for conjunctival malignancy.

GLAUCOMA SURGERY

Glaucoma can be managed in the usual manner. If the patient has been treated for an iris or posterior uveal melanoma. If the tumour is sterile, it should be safe to perform a drainage procedure, including the insertion of a Baerveldt or another implant. Painful neovascular glaucoma usually requires enucleation.

STRABISMUS SURGERY

Ocular motility disorders can follow muscle disinsertion performed during plaque or tantalum marker insertion or during trans-scleral local resection.

Surgical treatment of these conditions can be challenging because of extensive scarring and/or scleral thinning (after exoresection).

The surgeon considering surgery may therefore wish to discuss the case with an ocular oncologist before undertaking any surgical procedures.

MANAGEMENT OF DRY EYE

Methods include:

- **Mild:** education and environmental/dietary modifications; elimination of offending systemic medications, if possible; artificial tears, gels, ointments; eyelid therapy
- **Moderate:** anti-inflammatories; punctal plugs; secretagogues; moisture-chamber spectacles
- **Severe:** serum; contact lenses; permanent punctal occlusion
- **Incapacitating:** systemic anti-inflammatory agents; surgery (tarsorrhaphy, mucus membrane graft)

MANAGEMENT OF MEIBOMIAN GLAND DYSFUNCTION

Methods include:

- Antibiotics: tetracyclines, azithromycin
- Anti-inflammatory agents: cyclosporin A, steroids
- Hormone replacement therapy
- Fish-derived omega-e supplementation
- Meibum expression: intraductal meibomian gland probing, electronic heating devices

MANAGEMENT OF LIMBAL STEM-CELL DEFICIENCY

Methods include:

- Eyelid and conjunctival reconstruction: lysis of symblepharon; autologous conjunctival transplant; nasal/buccal mucosa graft; amniotic membrane graft
- Anti-inflammatory treatment: steroids; cyclosporine; tacrolimus
- Optimization of tear aqueous function: see above
- Meibomian gland dysfunction treatment: see above
- Surgical treatment: sequential sectorial conjunctival epitheliectomy; limbal stem-cell transplantation

TENTATIVE GUIDELINES FOR REGIONAL OCULAR ONCOLOGY SERVICES

INTRODUCTION

Regional ocular oncology services would provide significant benefits to patients and the National Health Service, as shown by the experience gained at Oxford Eye Hospital.

Patients with ocular tumours would receive care that is safer and more efficient than that provided in general ophthalmic clinics, avoiding non-essential hospital attendances and investigations. These measures would help reduce hospital waiting lists, also conserving resources so that they are available to patients in greater need.

Regional ocular oncology team members would also provide education to ophthalmologists in other subspecialties in their eye clinics, and to nurses, community optometrists, and others.

The purpose of regional ocular oncology services would be to complement care provided by supraregional ocular oncology services and not to compete with them.

The aim of these guidelines is to help hospitals establish, maintain and improve regional ocular oncology services across the UK.

OCULAR ONCOLOGY SERVICE

CORE TEAM

The core 'ocular oncology team' would comprise ophthalmologists, secretaries and nurses with special expertise in ocular oncology, referred to as 'ocular oncology specialists', 'ocular oncology secretaries' and 'ocular oncology nurses', respectively.

There would be two of each of these workers, serving as 'lead' and 'deputy', respectively, to provide continuity of service when one is not

available because of illness, vacation, or retirement.

All would work part-time in the ocular oncology service, dedicating two or three sessions to this service every week or on alternate weeks.

COMPETENCE

The ocular oncology specialists would develop and maintain competence in ocular oncology by:

- Support from supraregional ocular oncology centres
 - Observerships at ocular oncology centres
 - Mentorships from ocular oncologists
 - Attendance at ocular oncology MDT meetings
- Library facilities, including:
 - Full access to Pubmed
 - Oncology textbooks, in PDF form
 - Subscriptions to selected AI programs
- Attendances at ocular oncology seminars and symposia, remotely or in person
- Attendance at internal multidisciplinary ocular oncology team meetings
 - Weekly by members of the core team
 - Monthly, with associate members (e.g., photographers, etc)
 - Annually, with medical oncologists and other specialists
- Attendance at external multidisciplinary team meetings:
 - Other regional ocular oncology services
 - Supraregional ocular oncology services, as mentioned above
- Audits of different aspects of the service, such as:
 - Patient demographics (numbers, conditions, management, etc)
 - Outcomes of patients attending the regional ocular oncology service

- Patient satisfaction with ocular oncology service
- Waiting times, incidents, etc
- Annual inspections by an ocular oncologist from a supraregional ocular oncology centre and/or an ocular oncology specialist from another regional ocular oncology service
- Annual appraisals by experts in the field.

ASSOCIATES

The team work closely with ophthalmologists in other specialties, ophthalmic photographers, ultrasonographers, administrators, medical oncologists, and others.

OCULAR ONCOLOGY CLINICS

FACE-TO-FACE CLINIC

A face-to-face (F2F) ocular oncology clinic would be held one morning or afternoon each week.

This would be staffed by one ocular oncology specialist, one nurse, and an ophthalmology trainee.

Indications for referral to this clinic would be:

- Ocular tumours that cannot safely be assessed remotely, because they cannot be adequately imaged (e.g., choroidal tumours, such as naevi and treated melanomas extending beyond the range of available fundus cameras or involving the angle or ciliary body).
- Patients requiring in-depth counselling and emotional support, such as those with:
 - newly diagnosed malignances, such as ocular melanoma, metastases, carcinomas
 - suspected or proven local tumour relapses
 - other ocular morbidity, such as radiation-induced, 'toxic-tumour syndrome', cataract, glaucoma, etc.

- Patients requiring examination of the whole eye because of:
 - Previously treated retinoblastoma
 - Congenital ocular melanosis
 - BAP1 and DICER1 tumour-predisposition syndromes
 - Von Hippel Lindau disease

'VIRTUAL' CLINICS

Patients managed remotely by an ocular oncology specialist in a 'virtual' ocular oncology clinic would:

- Receive an appointment letter and information sheet with:
 - Appointment time and place
 - The planned care during that visit
 - Contact details if the patient has any questions or problems
- Attend the photography unit and/or ultrasound department for imaging consisting of colour photography, fundus autofluorescence imaging, optical coherence tomography, and/or ultrasonography, according to the tumour location and suspected diagnosis.
- Receive a phone call from an ocular oncology specialist or nurse, if communication by mail is considered inappropriate.
- Receive a copy of the ocular oncology specialist's report, with:
 - Definitive or suspected diagnosis
 - Planned management, consisting of:
 - Discharge with advice on self monitoring or surveillance by a community optometrist,
 - A photograph of the lesion in question, to take to a community optometrist at every visit, if surveillance by an optometrist is suggested.
 - Repeat virtual clinic appointment after a specified time interval,
 - Appointment for a F2F clinic visit, or referral to a supraregional ocular oncology service for expert care.

- Instructions and contact details in case any questions or problems arise.

ADMINISTRATIVE CLINIC

Patients would be listed in this clinic if:

- Requiring triage to a virtual clinic, F2F clinic when referred to the regional ocular oncology service by: a community optometrist, an ophthalmologist at the same hospital or another hospital, or a supraregional ocular oncology centre. Patients would be listed by the ocular oncology secretary on receipt of a referral.
- Requiring review of their status, of any reports and of any letters from a supraregional ocular oncology centre or another centre. Patients would be given 'appointments' on dates corresponding to deadlines by which actions must be taken (e.g., 1 week if tests of calcium metabolism, 2 weeks if conjunctival tumour biopsy, 1 month if referred to an ocular oncology centre, etc). This would help ensure that all reports and letters are all reviewed in a timely manner. These patients would be listed by the ocular oncology specialist or secretary.

PROTOCOLS

The following protocols would need to be prepared and regularly updated:

OPTOMETRISTS

- Examination of patients with a suspected ocular tumour
- Surveillance of patients with ocular tumours
- Counselling of patients
- Referral of patients to a regional eye hospital

NON-ONCOLOGY OPHTHALMOLOGISTS

- Examination of patients with a suspected ocular tumour
- Surveillance of patients with ocular tumours
- Counselling of patients
- Referral of patients to a regional ocular oncology service

OCULAR ONCOLOGY SPECIALISTS

- Triage of new referrals
- Patient care in virtual clinics
- Patient care in F2F clinics
- Patient care in administrative clinics

OTHERS

- Ocular oncology secretaries
- Ocular oncology nurses
- Photographers
- Ultrasonographers
- Etc

These protocols would complement and not replace any guidelines prepared by the College of Optometrists, the Royal College of Ophthalmologists, and other official bodies.

FURTHER READING

- Damato, B. E. (2022). Clinical Atlas of Ocular Oncology. Springer International Publishing
- Singh, A. D., & Damato, B. E. (Eds.). (2025). Clinical Ophthalmic Oncology: Basic Principles (4th ed.). Springer International Publishing
- Bhupendra, C.K., Pe'er, J., & Singh, A. D. (Eds.). (2025). Clinical Ophthalmic Oncology: Eyelid Tumors (4th ed.). Springer International Publishing
- Pe'er, J., Singh, A. D., & Damato, B. E. (Eds.). (2025). Clinical Ophthalmic Oncology: Conjunctival Tumors (4th ed.). Springer International Publishing
- Damato, B., & Singh, A. D. (Eds.). (2025). Clinical Ophthalmic Oncology: Uveal Tumors (4th ed.). Springer.
- Singh, A. D., & Damato, B. E. (Eds.). (2025). Clinical Ophthalmic Oncology: Retinal Tumors. (4th ed.). Springer International Publishing
- Berry J.L., & Singh, A. D. (Eds.). (2025). Clinical Ophthalmic Oncology: Retinoblastoma. (4th ed.). Springer International Publishing
- Shields J.A., & Shields CL. (2015). Intraocular tumors: An Atlas and Textbook. Lippincott Williams & Wilkins (LWW)
- Shields J.A., & Shields C.L. (2015). Eyelid, Conjunctival and Orbital Tumours: An Atlas and Textbook. Lippincott Williams & Wilkins (LWW)
- Clinical Management Guidelines: Pigmented fundus lesions. The College of Optometrists. <https://www.college-optometrists.org/clinical-guidance/clinical-management-guidelines/pigmentedfunduslesions>
- Referral pathways for adult ocular tumours. The Royal College of Ophthalmologists. <https://www.rcophth.ac.uk/resources-listing/referral-pathways-for-adult-ocular-tumours/>

We hope you have found this e-book useful. Please send any comments and suggestions to:
Bertil.Damato@nhs.net

Thank you

3/1/2025

Ocular Oncology Service
Moorfields Eye Hospital
162 City Road
London
EC1V 2PD
UK